

Acute pancreatitis in Crohn's disease: diagnostic value of diffusion-weighted MRI

Published on 06.11.2016

DOI: 10.1594/EURORAD/CASE.14183

ISSN: 1563-4086

Section: Abdominal imaging

Area of Interest: Pancreas

Procedure: Diagnostic procedure

Procedure: Cholangiography

Procedure: Dilation

Imaging Technique: CT

Imaging Technique: MR

Imaging Technique: MR-Diffusion/Perfusion

Special Focus: Acute Case Type: Clinical Cases

Authors: Tonolini Massimo, MD.

Patient: 43 years, male

Clinical History:

The patient is a male smoker suffering from upper abdominal pain radiating to his back. Medical history included appendectomy, recent diagnosis and surgical treatment of Crohn's disease one year earlier. Physical examination excluded peritonism, fever and bowel obstruction. Laboratory studies revealed leukocytosis (11.600 cells/mm³), elevated C-reactive protein (54 mg/L) and serum lipase (1400 U/L).

Imaging Findings:

Twenty months earlier, before diagnosis of Crohn's disease (CD), he experienced mild acute pancreatitis (AP) with near-normal CT (Fig.1) and MR-cholangiopancreatography (Fig.2) findings apart from subtle peripancreatic fat stranding at the tail. Suspected autoimmune pathogenesis was not confirmed by immunologic studies.

Eight months later, the patient was diagnosed with severely active ileo-colonic CD. After initial steroid treatment, infliximab was suspended because of allergy, and surgical ileocecal resection was performed plus cholecystectomy and adhesiolysis.

A year after surgery, this new AP bout was again studied with CT (Fig.3) and MR (Fig.4) with inconclusive imaging findings. The addition of diffusion-weighted (DW) MRI (Fig.5) revealed homogeneously increased pancreatic signal intensity compared to normal control (Fig.6) with corresponding abnormally low apparent diffusion coefficients (ADC). Therefore, DW-MRI confirmed the diagnosis of AP over unspecific enzyme elevation, probably secondary to iatrogenic effect of drugs (probably metronidazole) since cholelithiasis, alcohol and autoimmune (negative autoantibodies) were excluded.

Discussion:

Among the varied spectrum of its extraintestinal manifestations, Crohn's disease (CD) has a well-known association with acute and chronic pancreatic disorders. In patients with CD, the incidence of acute pancreatitis (AP) reaches 1.4% and is 3- to 4-fold higher compared to control populations even after adjusting for other risk factors. Most cases occur in young adults (between 20 and 50 years of age) with a female predominance and smoking as key risk factor. The majority of AP occur within 2 years after CD diagnosis; less than 10% of patients suffer AP before CD diagnosis is established CD or synchronously with the onset of intestinal CD [1-6].

The increased incidence of AP is multifactorial and involves a combination of gallstone disease, adverse effect of

medications, and intrinsic immunologic disturbances. Compared to the general population, patients with CD have higher (13-34%) prevalence of cholesterol, mixed and pigment-type gallstones secondary to ileal disease. Several drugs are known to cause AP from possible idiosyncratic mechanism, such as thiopurines, sulfasalazine, 5-aminosalicylic acids, metronidazole and steroids; azathioprine has the higher incidence (7.3%) and strongest causal association with AP. Idiopathic cases are attributed to direct pancreatic damage as a true extraintestinal phenomenon [1-6].

In CD, the diagnosis of AP requires at least 2 out of 3 criteria (a-consistent abdominal pain, b-serum lipase or amylase greater than 3 times the upper normal limit, c-consistent CT or MRI findings). However, recurrent unspecific abdominal pain is common in the setting of CD, and benign increase of pancreatic enzymes without true imaging-confirmed AP are common (9-17%) in CD [1-6].

As in this case, in patients with consistent clinical and laboratory findings but inconclusive sonographic and CT appearances, the use of diffusion-weighted (DW) MRI may help to confirm the diagnosis of mild AP over nonspecific changes since it allows differentiation between normal, inflamed and necrotic pancreas without intravenous contrast. Albeit values are inconsistent between different scanners and protocols, mean apparent diffusion coefficient (ADC) values in AP are significantly decreased in AP compared to healthy glandular parenchyma and cut-off values of 1.5-1.6 have been proposed for diagnosing AP [7-10].

The same would be probably also useful for drug-induced AP, which represents the third cause (5.3%) of AP in the general population after biliary and alcohol [11, 12]. The severity, treatment and prognosis of AP in CD is analogous to those in the general population, and drug-induced occurrences are generally uncomplicated and self-limiting [1-6].

Differential Diagnosis List: Drug-induced mild acute pancreatitis in Crohn's disease, Biliary acute pancreatitis from recurrent lithiasis, Autoimmune pancreatitis, Unspecific enzyme elevations with normal pancreatitis, Alcohol pancreatitis, Pancreas divisum, Acute duodenal peptic disease

Final Diagnosis: Drug-induced mild acute pancreatitis in Crohn's disease

References:

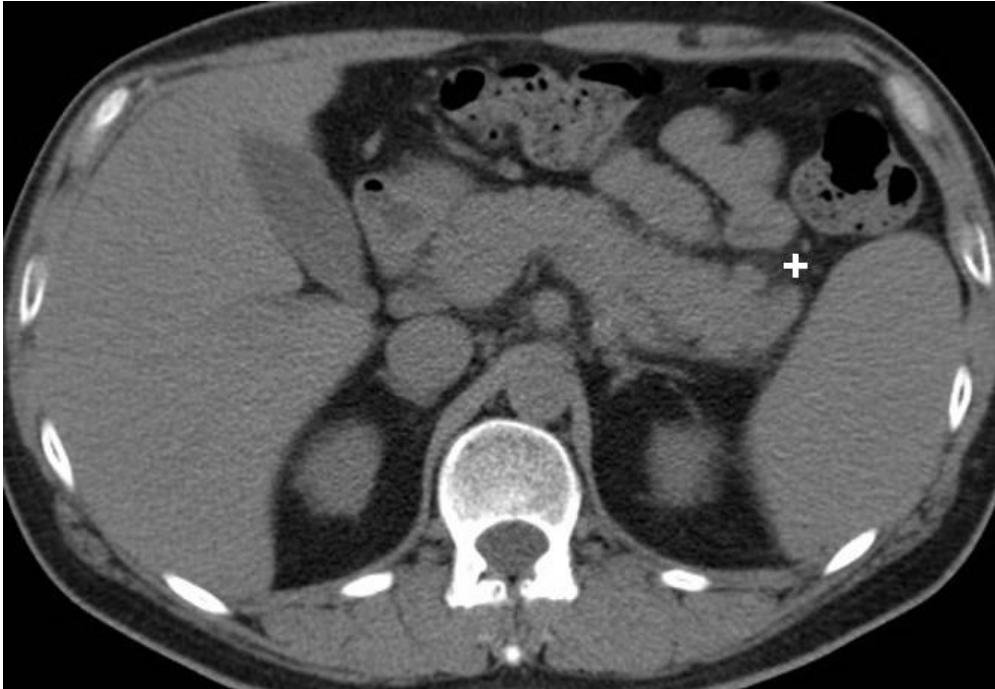
- Chen YT, Su JS, Tseng CW, et al. (2016) Inflammatory bowel disease on the risk of acute pancreatitis: A population-based cohort study. *J Gastroenterol Hepatol* 31:782-787 (PMID: [26412125](#))
- Trikudanathan G, Navaneethan U (2011) Association of pancreatitis with inflammatory bowel disease. *J Clin Gastroenterol* 45:83 (PMID: [20495468](#))
- Pitchumoni CS, Rubin A, Das K (2010) Pancreatitis in inflammatory bowel diseases. *J Clin Gastroenterol* 44:246-253 (PMID: [20087199](#))
- Antonini F, Pezzilli R, Angelelli L, et al. (2016) Pancreatic disorders in inflammatory bowel disease. *World. J Gastrointest Pathophysiol* 7:276-282 (PMID: [27574565](#))
- Ramos LR, Sachar DB, DiMaio CJ, et al. (2016) Inflammatory Bowel Disease and Pancreatitis: A Review. *J Crohns Colitis* 10:95-104 (PMID: [26351384](#))
- Jasdanwala S, Babyatsky M (2015) Crohn's disease and acute pancreatitis. A review of literature. *JOP* 16:136-142. (PMID: [25791546](#))
- Hocaoglu E, Aksoy S, Akarsu C, et al. (2015) Evaluation of diffusion-weighted MR imaging in the diagnosis of mild acute pancreatitis. *Clin Imaging* 39:463-467 (PMID: [25457519](#))
- Lee NK, Kim S, Kim DU, et al. (2015) Diffusion-weighted magnetic resonance imaging for non-neoplastic conditions in the hepatobiliary and pancreatic regions: pearls and potential pitfalls in imaging interpretation. *Abdom Imaging* 40:643-662. (PMID: [25216848](#))
- de Freitas Tertulino F, Schraibman V, Ardengh JC, et al. (2014) Diffusion-weighted magnetic resonance imaging indicates the severity of acute pancreatitis. *Abdom Imaging* 40:265-271 (PMID: [25070771](#))
- Thomas S, Kayhan A, Lakadamyali H, et al. (2012) Diffusion MRI of acute pancreatitis and comparison with normal individuals using ADC values. *Emerg Radiol* 19:5-9 (PMID: [21927794](#))
- Vinklerova I, Prochazka M, Prochazka V, et al. (2010) Incidence, severity, and etiology of drug-induced acute

pancreatitis. Dig Dis Sci 55:2977-2981 (PMID: [20499176](#))

van Geenen EJ, de Boer NK, Stassen P, et al. (2010) Azathioprine or mercaptopurine-induced acute pancreatitis is not a disease-specific phenomenon. Aliment Pharmacol Ther 31:1322-1329 (PMID: [20222913](#))

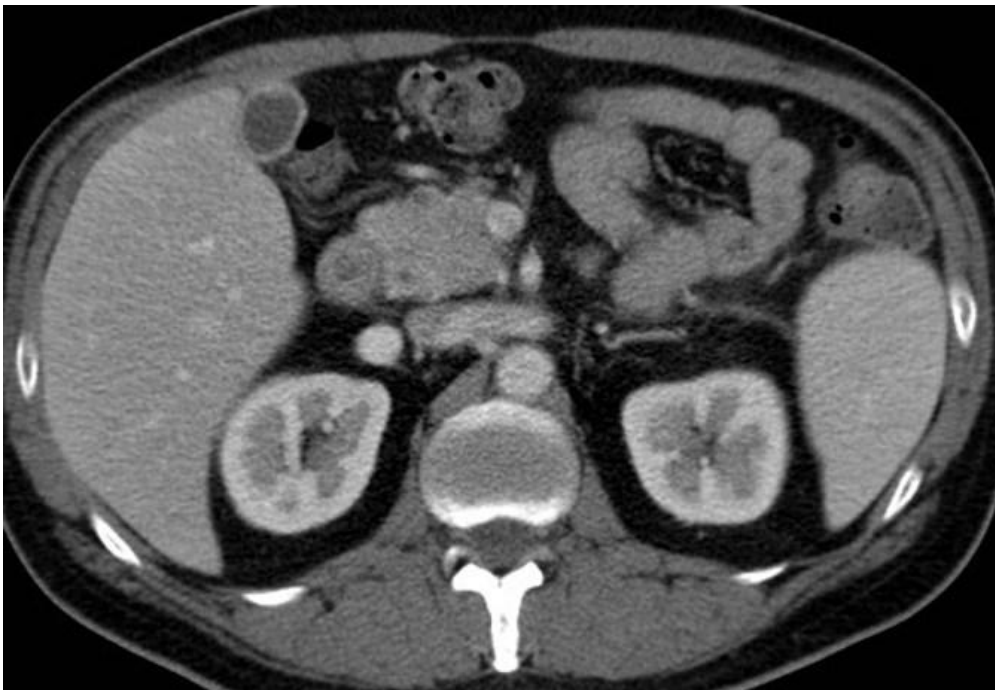
Figure 1

a



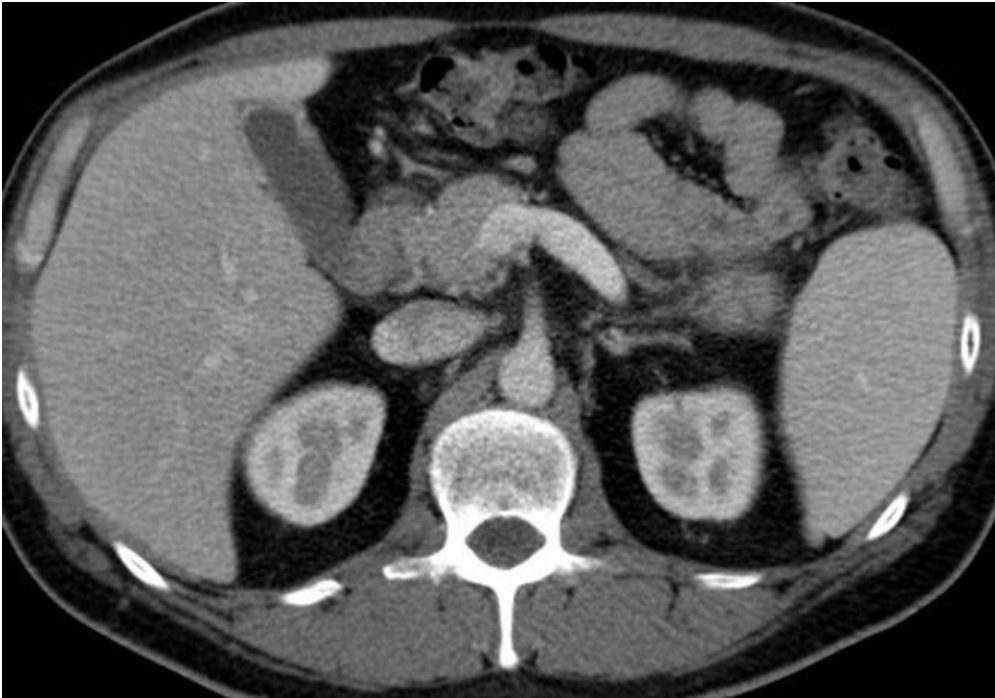
Description: Preliminary unenhanced acquisition revealed normal-sized pancreas with mild fat stranding (+) surrounding the tail, in absence of peripancreatic fluid collections, fascial and peritoneal effusion. **Origin:** Tonolini M, Radiology Department, "Luigi Sacco" University Hospital – Milan (Italy)

b



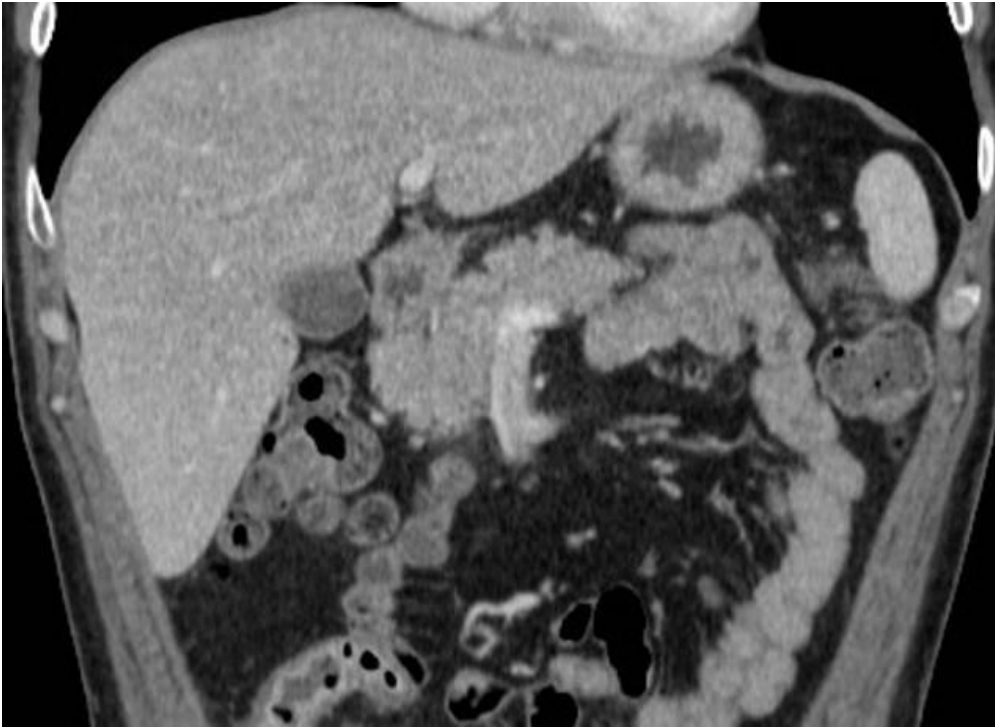
Description: Contrast-enhanced images (b...e) showed normal size and configuration of the pancreatic gland, with normal homogeneous enhancement thereby excluding necrosis. Confirmed absence of peripancreatic fluid collections, fascial and peritoneal effusion. **Origin:** Tonolini M, Radiology Department, "Luigi Sacco" University Hospital – Milan (Italy)

c



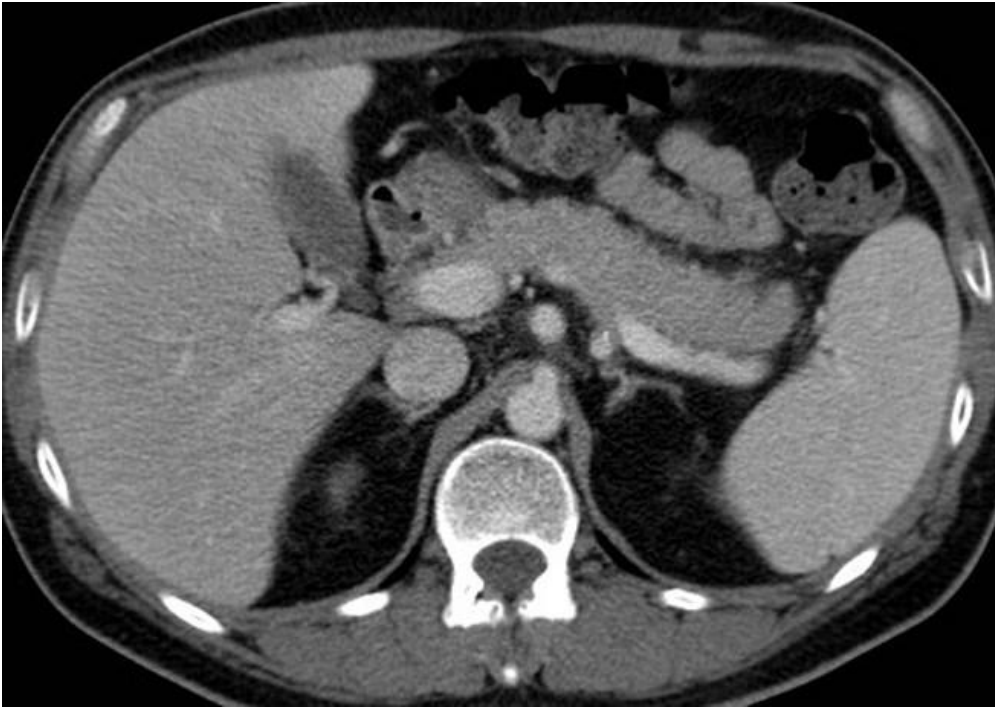Description: Contrast-enhanced images (b...e) showed normal size and configuration of the pancreatic gland, with normal homogeneous enhancement thereby excluding necrosis. Confirmed absence of peripancreatic fluid collections, fascial and peritoneal effusion. **Origin:** Tonolini M, Radiology Department, "Luigi Sacco" University Hospital – Milan (Italy)

d



Description: Contrast-enhanced images (b...e) showed normal size and configuration of the pancreatic gland, with normal homogeneous enhancement thereby excluding necrosis. Confirmed absence of peripancreatic fluid collections, fascial and peritoneal effusion. **Origin:** Tonolini M, Radiology Department, "Luigi Sacco" University Hospital – Milan (Italy)

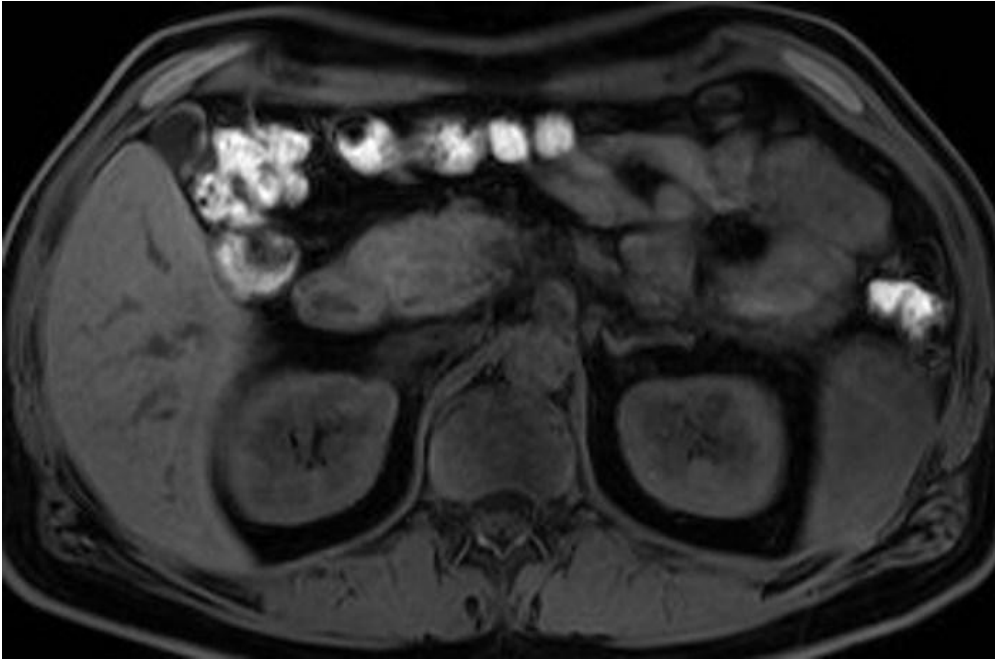
e



Description: Contrast-enhanced images (b...e) showed normal size and configuration of the pancreatic gland, with normal homogeneous enhancement thereby excluding necrosis. Confirmed absence of peripancreatic fluid collections, fascial and peritoneal effusion. **Origin:** Tonolini M, Radiology Department, "Luigi Sacco" University Hospital – Milan (Italy)

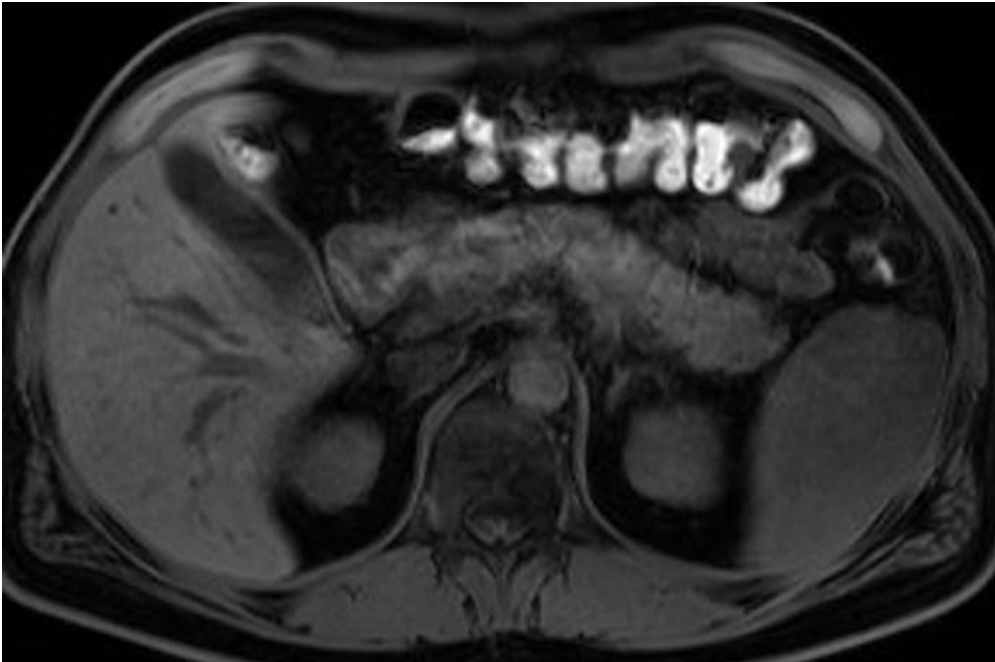
Figure 2

a



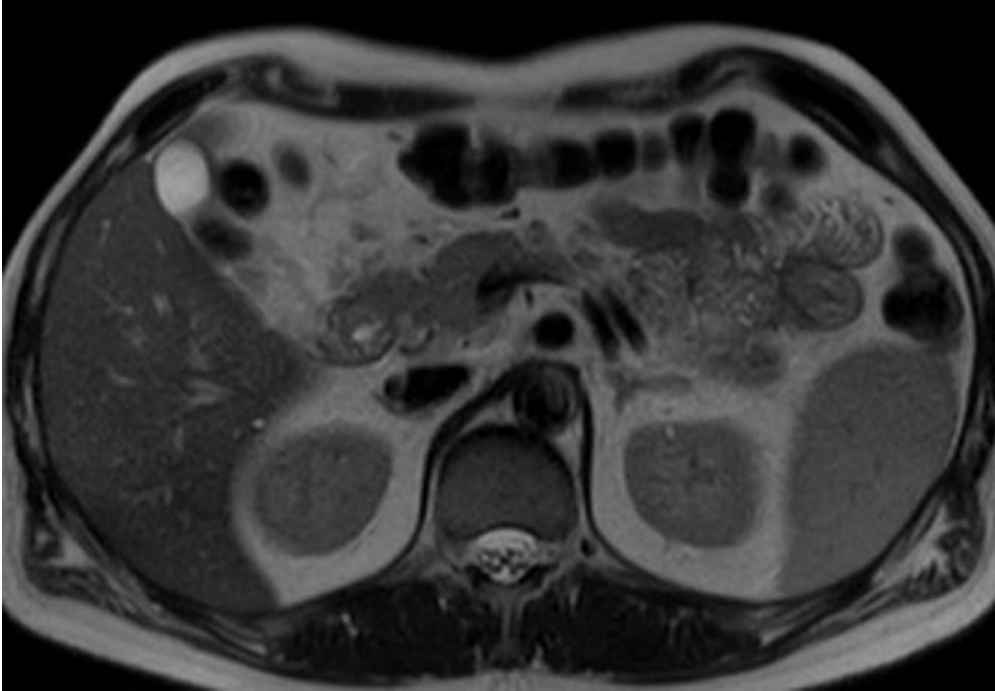
Description: At hospital discharge, fat-suppressed T1-weighted images (a,b) confirmed normal size and configuration of the pancreatic gland. **Origin:** Tonolini M, Radiology Department, "Luigi Sacco" University Hospital – Milan (Italy)

b



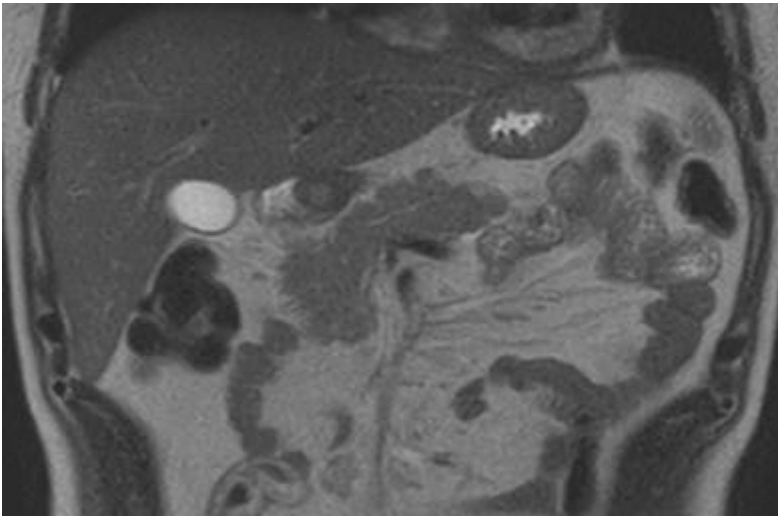
Description: At hospital discharge, fat-suppressed T1-weighted images (a,b) confirmed normal size and configuration of the pancreatic gland. **Origin:** Tonolini M, Radiology Department, "Luigi Sacco" University Hospital – Milan (Italy)

c



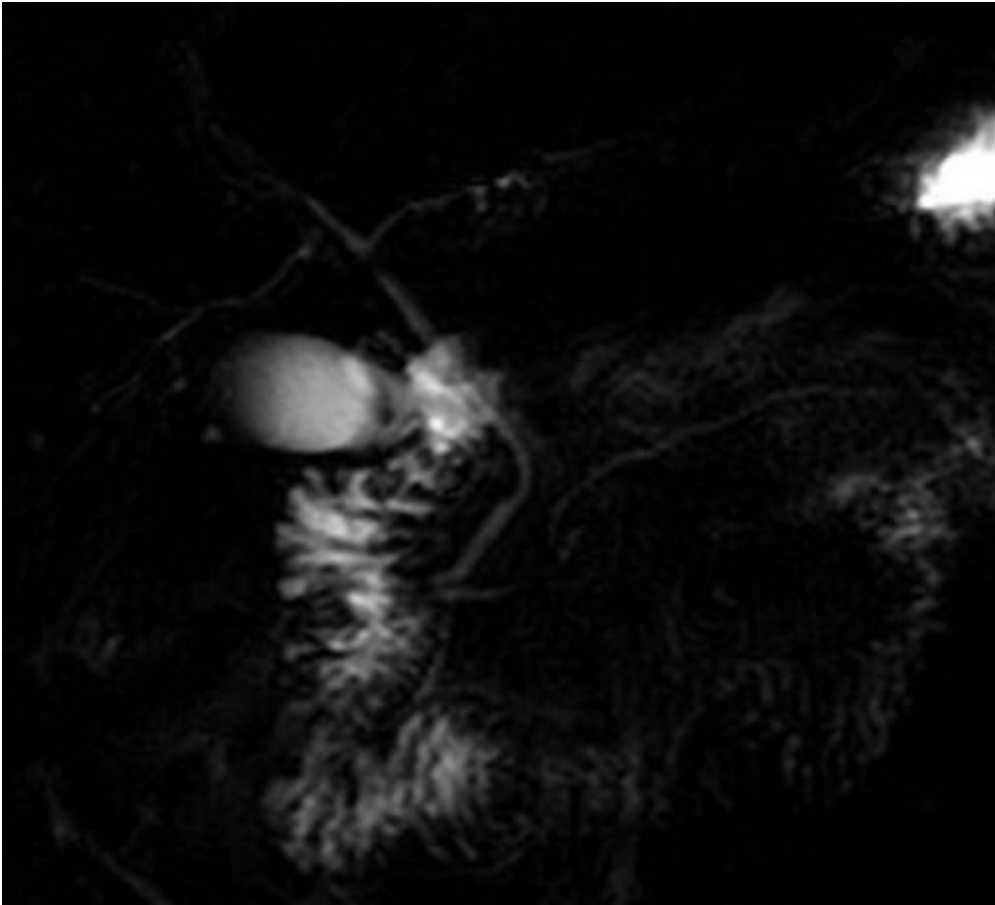
Description: Axial (c) and coronal (d) T2-weighted images confirmed normal size, configuration and signal intensity of the pancreatic gland. Absence of peripancreatic collections, fascial fluid and peritoneal effusion. **Origin:** Tonolini M, Radiology Department, "Luigi Sacco" University Hospital – Milan (Italy)

d



Description: Axial (c) and coronal (d) T2-weighted images confirmed normal size, configuration and signal intensity of the pancreatic gland. Absence of peripancreatic collections, fascial fluid and peritoneal effusion. **Origin:** Tonolini M, Radiology Department, "Luigi Sacco" University Hospital – Milan (Italy)

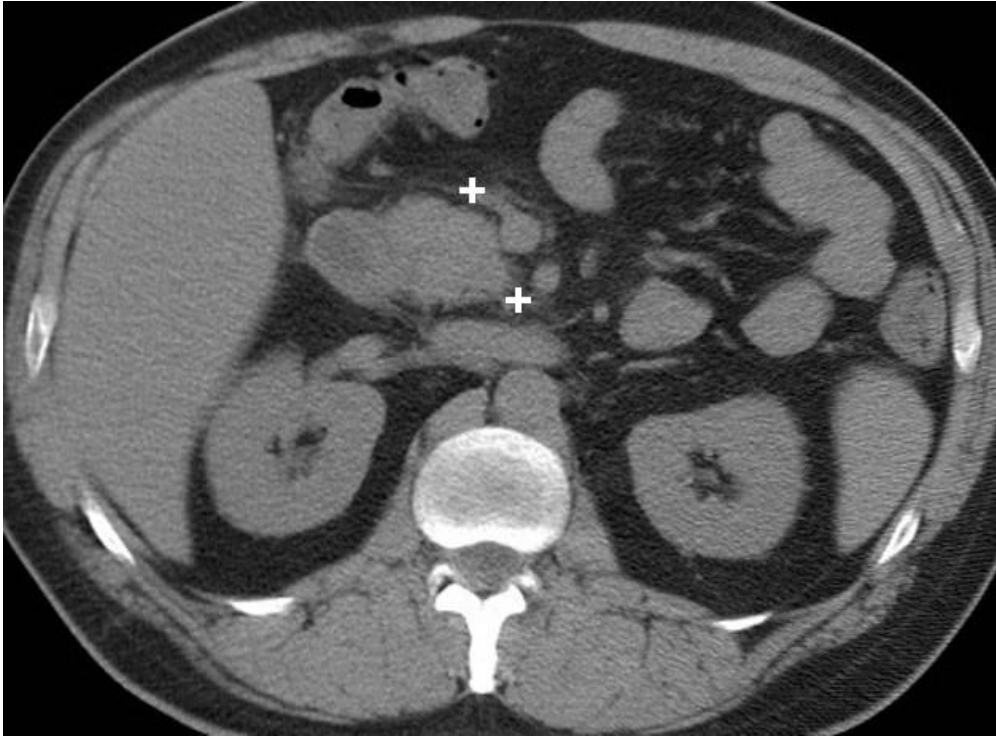
e



Description: MRCP images showed normally distended gallbladder, non-dilated intrahepatic bile ducts, normal caliber of the main bile ducts without appreciable lithiasis. The normal-appearing main pancreatic duct of Wirsung excluded pancreas divisum as possible cause of pancreatitis. **Origin:** Tonolini M, Radiology Department, "Luigi Sacco" University Hospital – Milan (Italy)

Figure 3

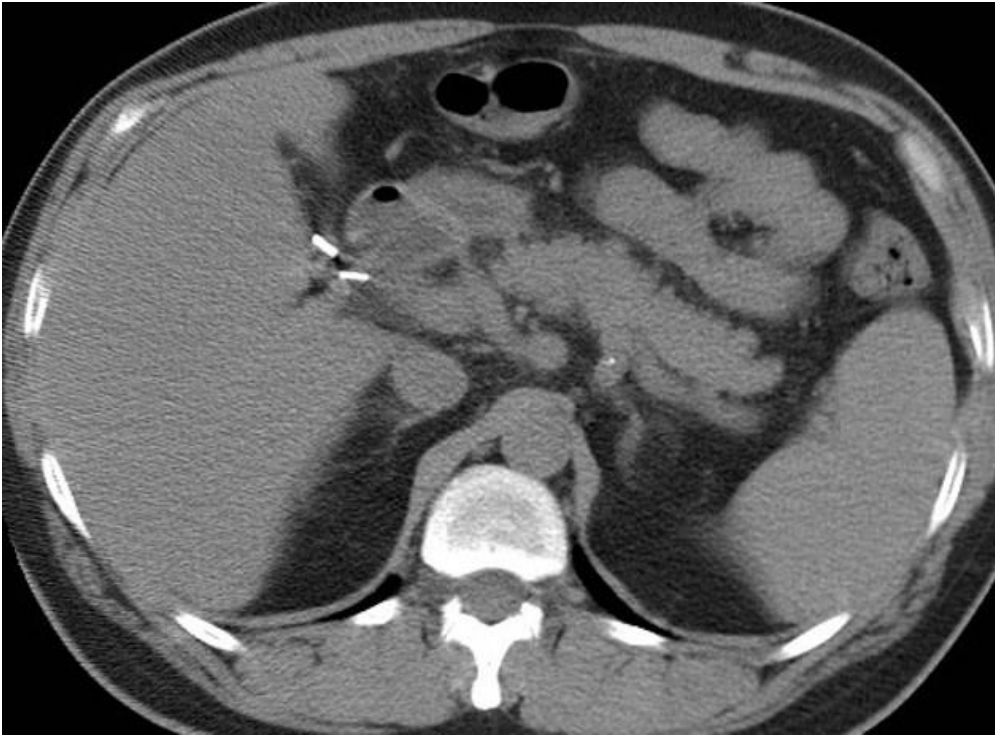
a



Description: Preliminary unenhanced images showed post-cholecystectomy status (note metallic clips), normal size and configuration of the pancreas, subtle fat stranding (+) surrounding the pancreatic head and uncinate process. Absence of peripancreatic collections, fascial fluid and peritoneal effusion.

Origin: Tonolini M, Radiology Department, "Luigi Sacco" University Hospital – Milan (Italy)

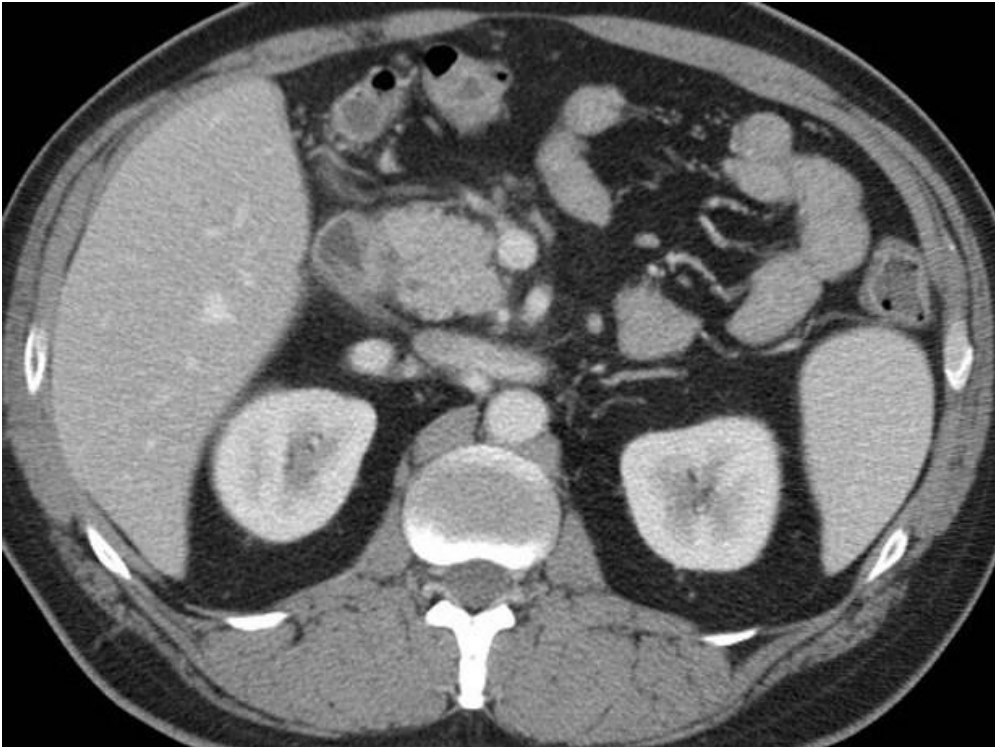
b



Description: Preliminary unenhanced images showed post-cholecystectomy status (note metallic clips), normal size and configuration of the pancreas, subtle fat stranding (+) surrounding the pancreatic head and uncinate process. Absence of peripancreatic collections, fascial fluid and peritoneal effusion.

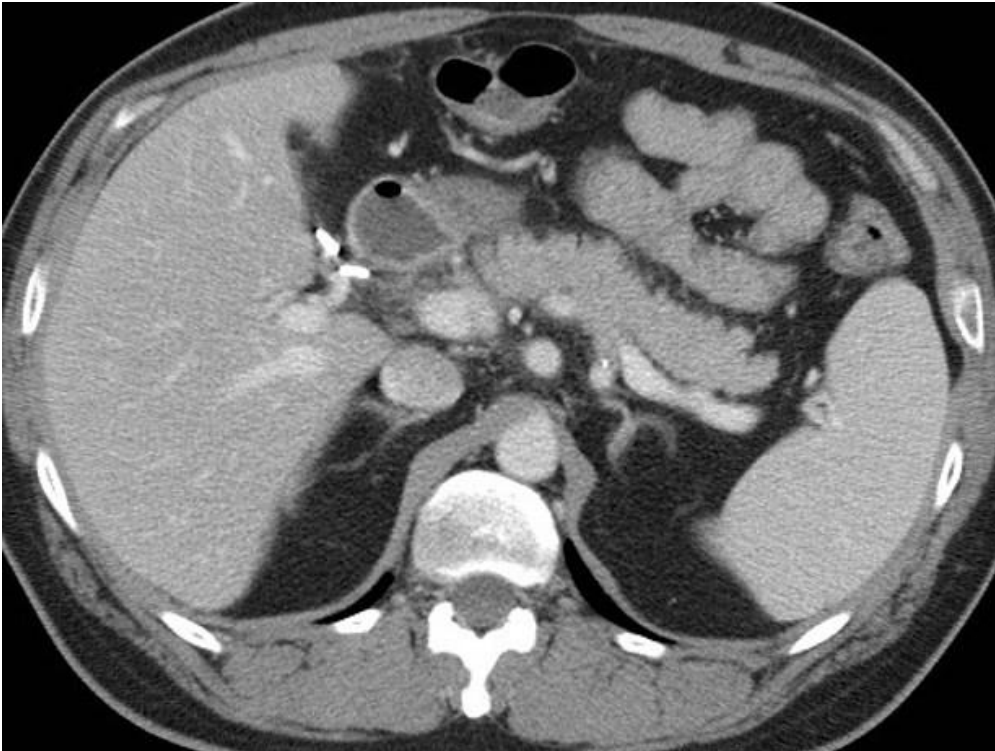
Origin: Tonolini M, Radiology Department, "Luigi Sacco" University Hospital – Milan (Italy)

c



Description: Post-contrast acquisition confirmed normal-sized pancreas with preserved homogeneous enhancement, absence of peripancreatic collections, fascial fluid and peritoneal effusion. **Origin:** Tonolini M, Radiology Department, "Luigi Sacco" University Hospital – Milan (Italy)

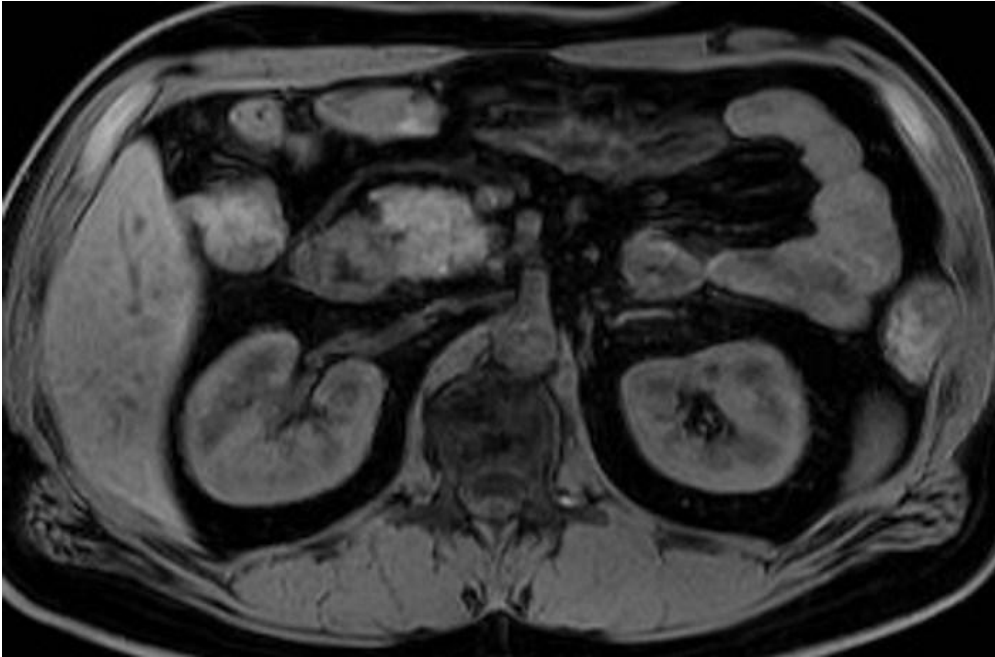
d



Description: Post-contrast acquisition confirmed normal-sized pancreas with preserved homogeneous enhancement, absence of peripancreatic collections, fascial fluid and peritoneal effusion. Note metallic clips in d. **Origin:** Tonolini M, Radiology Department, "Luigi Sacco" University Hospital – Milan (Italy)

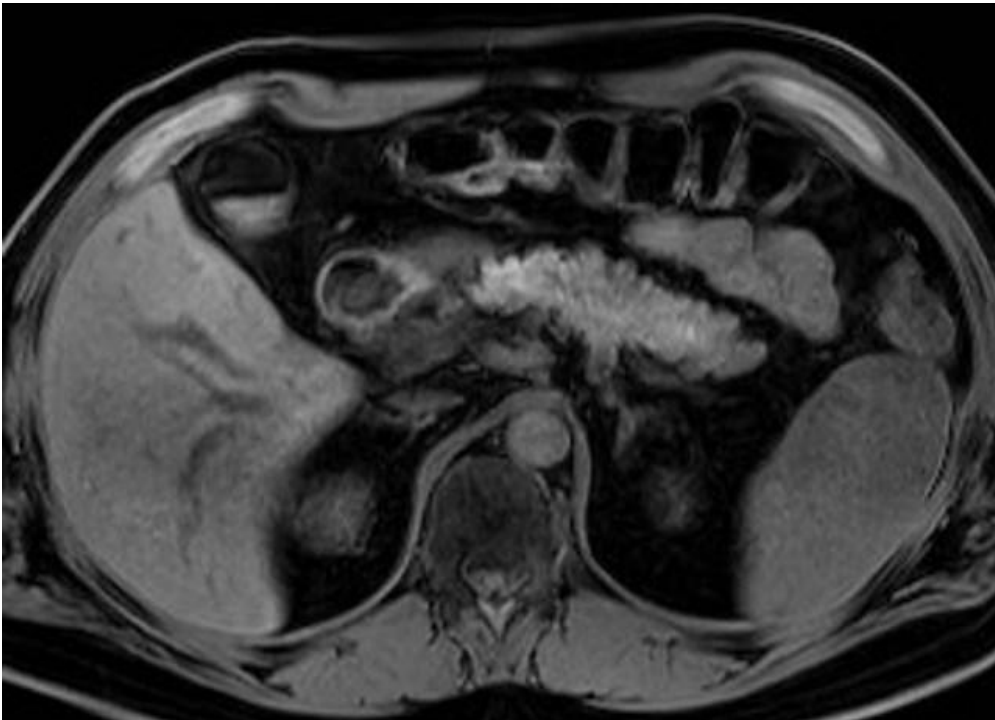
Figure 4

a



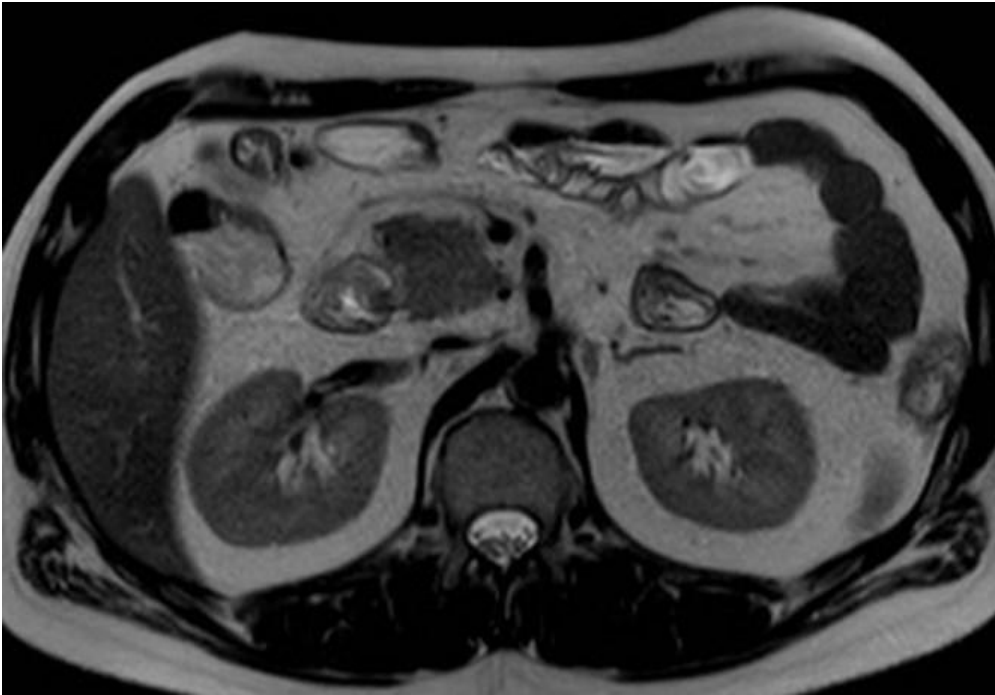
Description: Fat-suppressed T1-weighted images showed normal size and configuration of the pancreatic gland, unchanged compared to Fig.2. Note previous cholecystectomy. **Origin:** Tonolini M, Radiology Department, "Luigi Sacco" University Hospital – Milan (Italy)

b



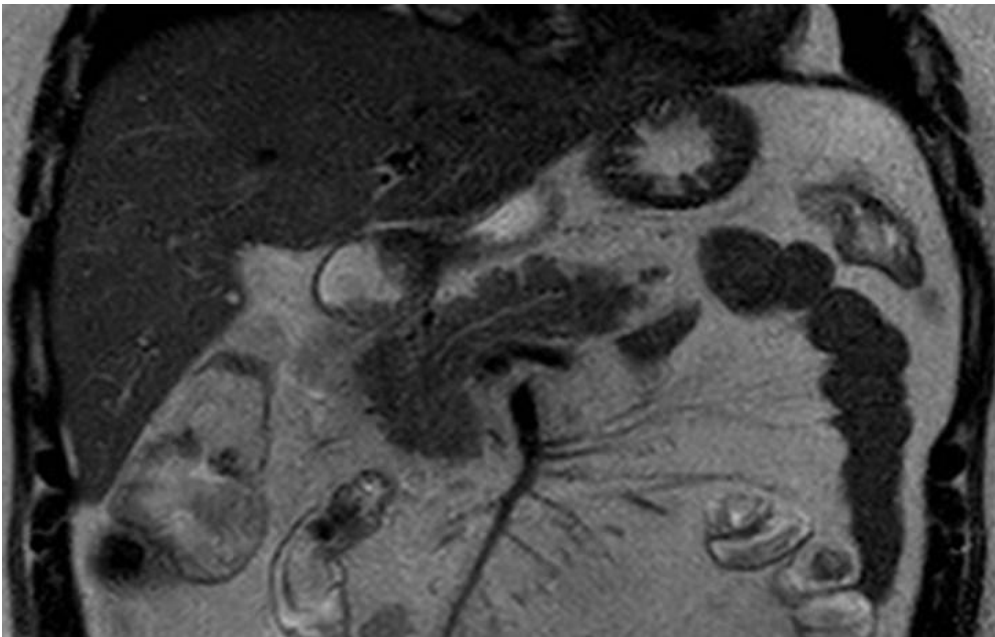
Description: Fat-suppressed T1-weighted images showed normal size and configuration of the pancreatic gland, unchanged compared to Fig.2. Note previous cholecystectomy. **Origin:** Tonolini M, Radiology Department, "Luigi Sacco" University Hospital – Milan (Italy)

c



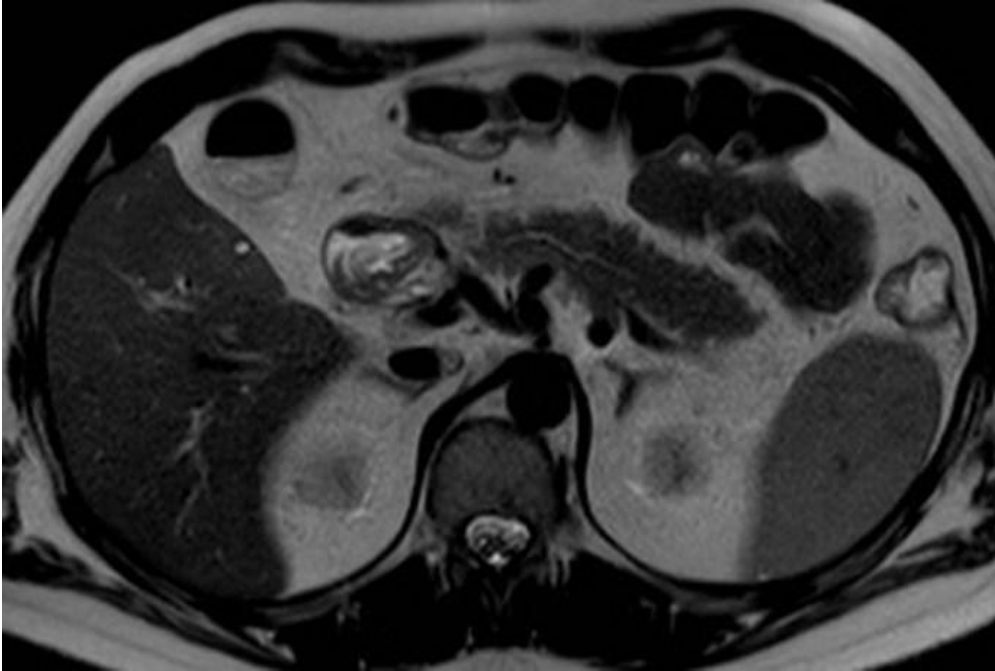
Description: T2-weighted images (c...e) showed normal size, configuration and signal intensity of the pancreatic gland, unchanged from Figure 2. Persistent absence of peripancreatic collections, fascial fluid and peritoneal effusion. Note previous cholecystectomy. **Origin:** Tonolini M, Radiology Department, "Luigi Sacco" University Hospital – Milan (Italy)

d



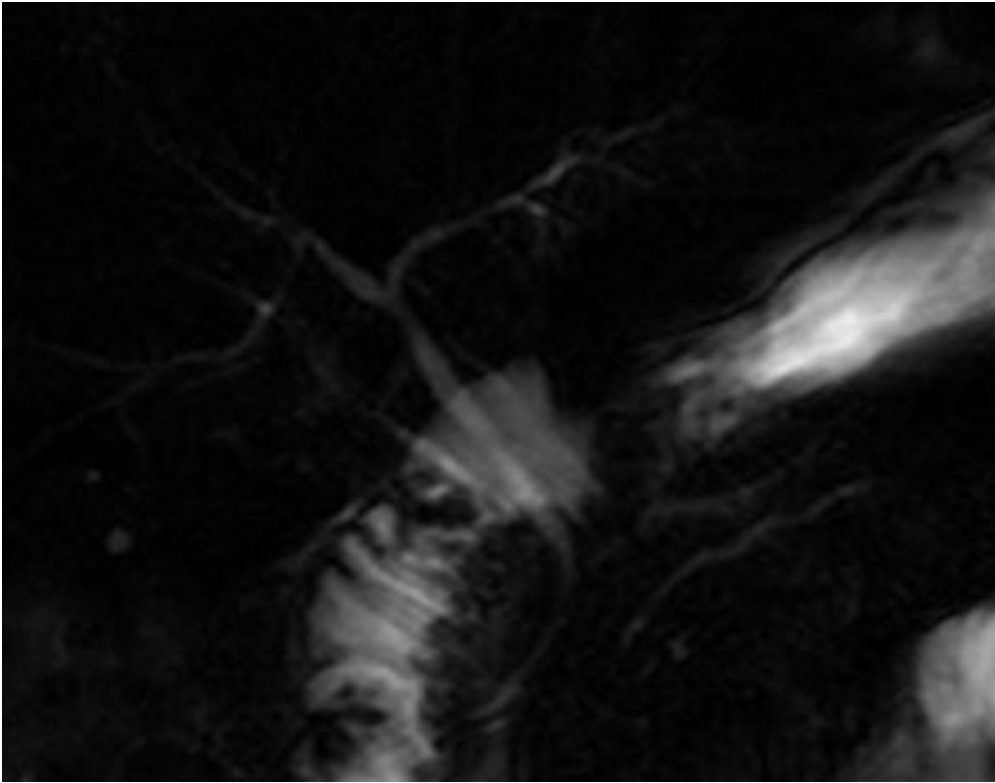
Description: T2-weighted images (c...e) showed normal size, configuration and signal intensity of the pancreatic gland, unchanged from Figure 2. Persistent absence of peripancreatic collections, fascial fluid and peritoneal effusion. Note previous cholecystectomy. **Origin:** Tonolini M, Radiology Department, "Luigi Sacco" University Hospital – Milan (Italy)

e



Description: T2-weighted images (c...e) showed normal size, configuration and signal intensity of the pancreatic gland, unchanged from Figure 2. Persistent absence of peripancreatic collections, fascial fluid and peritoneal effusion. Note previous cholecystectomy. **Origin:** Tonolini M, Radiology Department, "Luigi Sacco" University Hospital – Milan (Italy)

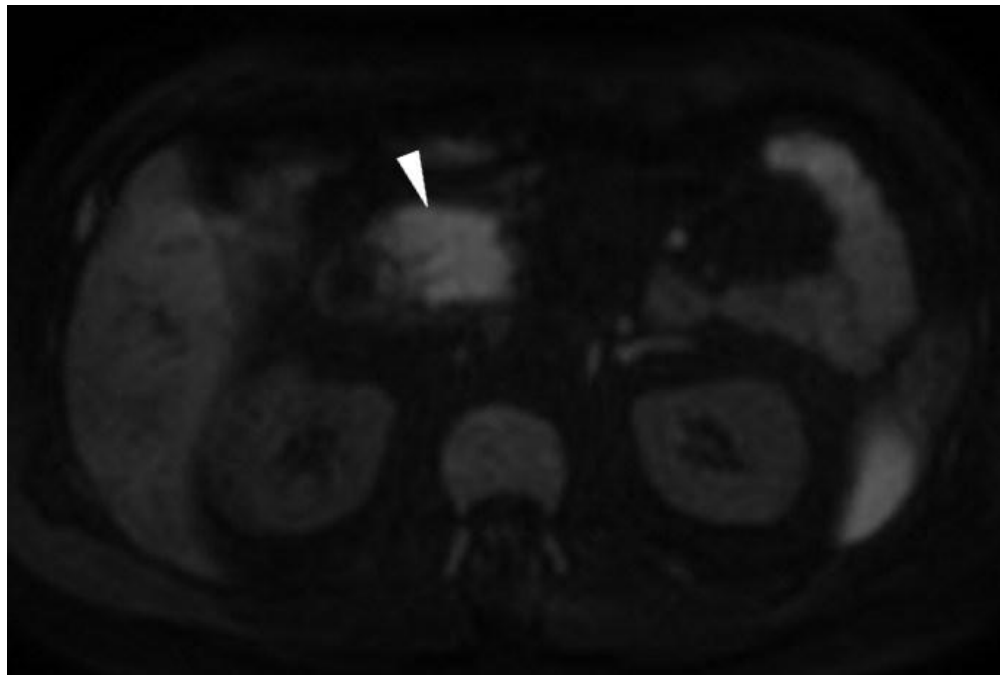
f



Description: MRCP showed non-dilated intrahepatic bile ducts, long cystic duct remnant after cholecystectomy, normal caliber of the main bile duct without appreciable lithiasis, normal-appearing main pancreatic duct of Wirsung. **Origin:** Tonolini M, Radiology Department, "Luigi Sacco" University Hospital – Milan (Italy)

Figure 5

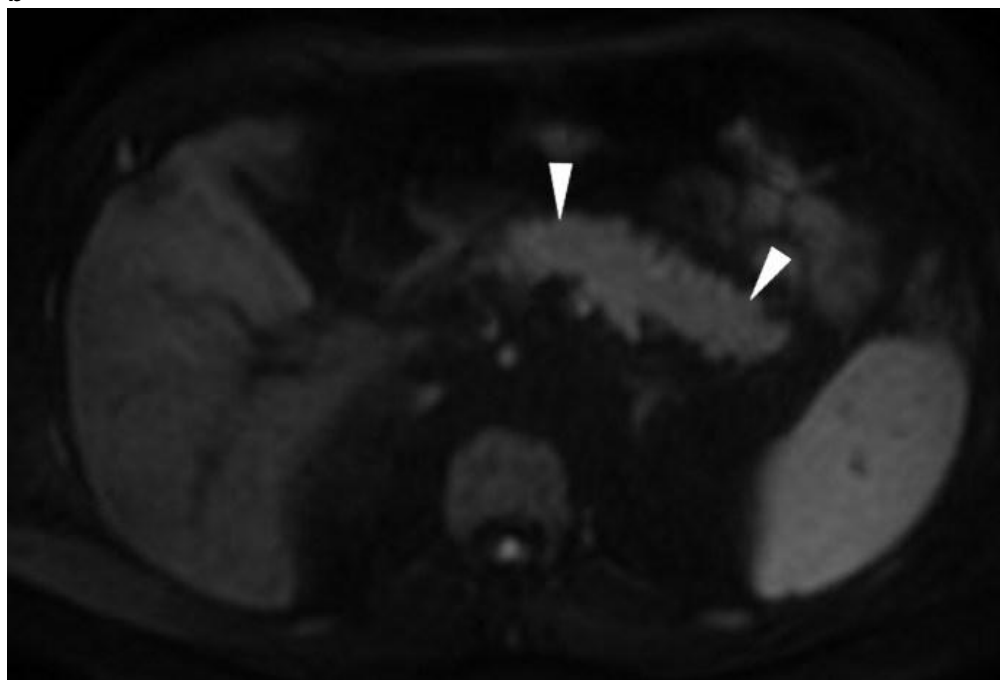
a



Description: Diffusion-weighted (b=800) images (a,b) showed homogeneously hyperintense signal of the pancreatic gland (arrowheads), compared to usual pancreatic appearance as shown in Figure 6.

Origin: Tonolini M, Radiology Department, "Luigi Sacco" University Hospital – Milan (Italy)

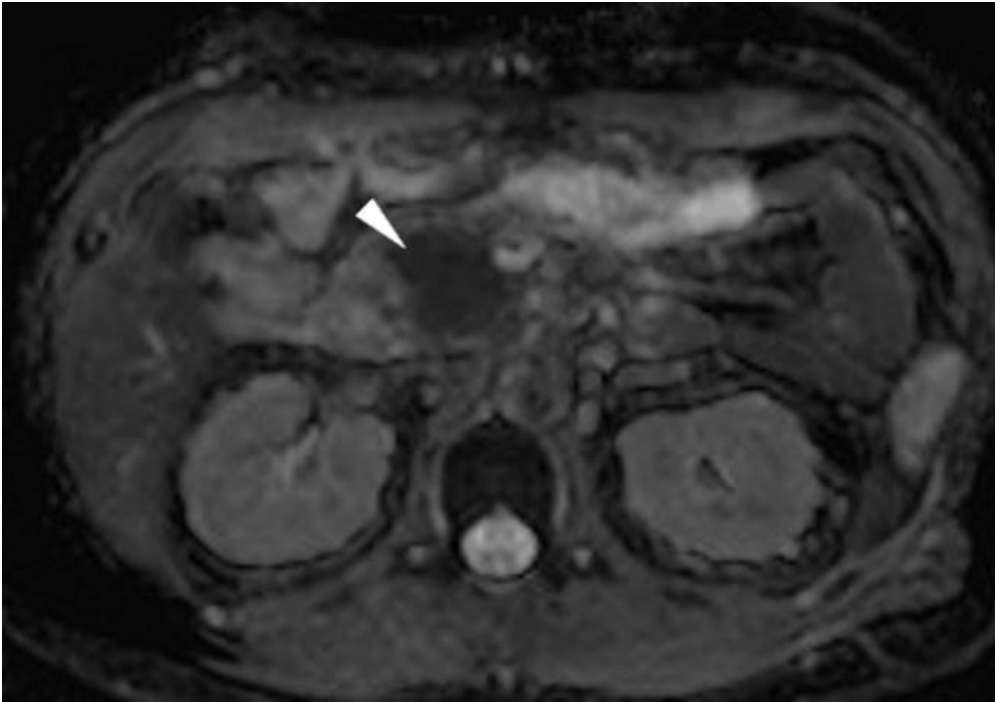
b



Description: Diffusion-weighted (b=800) images (a,b) showed homogeneously hyperintense signal of the pancreatic gland (arrowheads), compared to usual pancreatic appearance as shown in Figure 6.

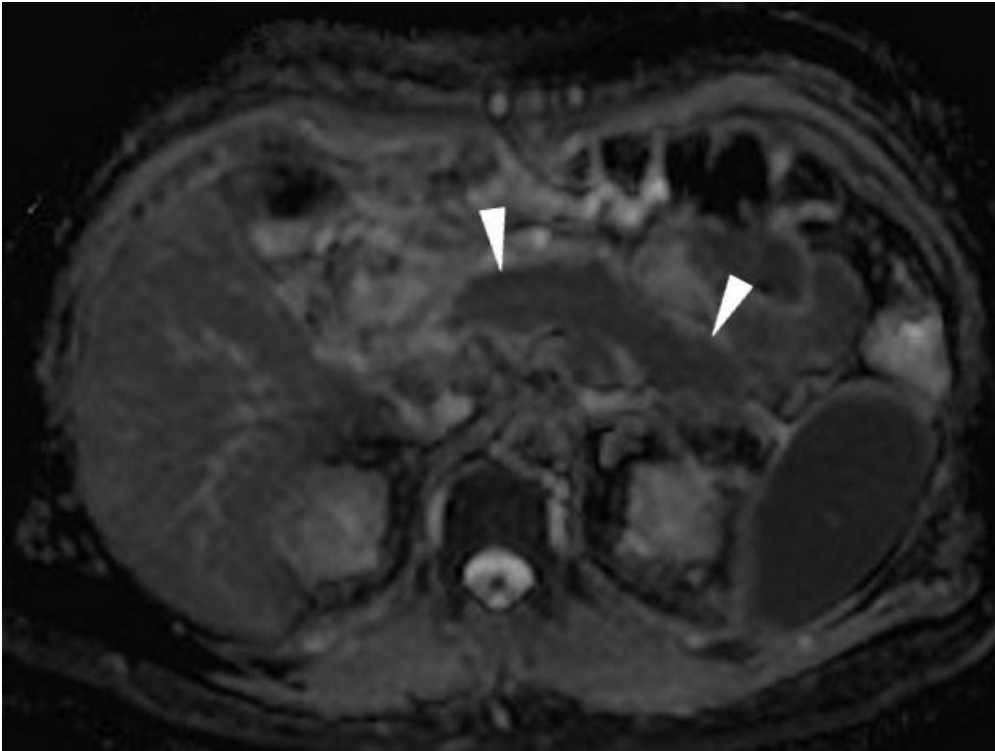
Origin: Tonolini M, Radiology Department, "Luigi Sacco" University Hospital – Milan (Italy)

c



Description: Apparent diffusion coefficient (ADC) maps (c,d) showed corresponding strong hypointensity of the pancreas (arrowheads), compared to usual appearance in Figure 6. Measured ADC values ranged between 0.85 and $1.08 \times 10^{-3} \text{ mm}^2/\text{s}$. **Origin:** Tonolini M, Radiology Department, "Luigi Sacco" University Hospital – Milan (Italy)

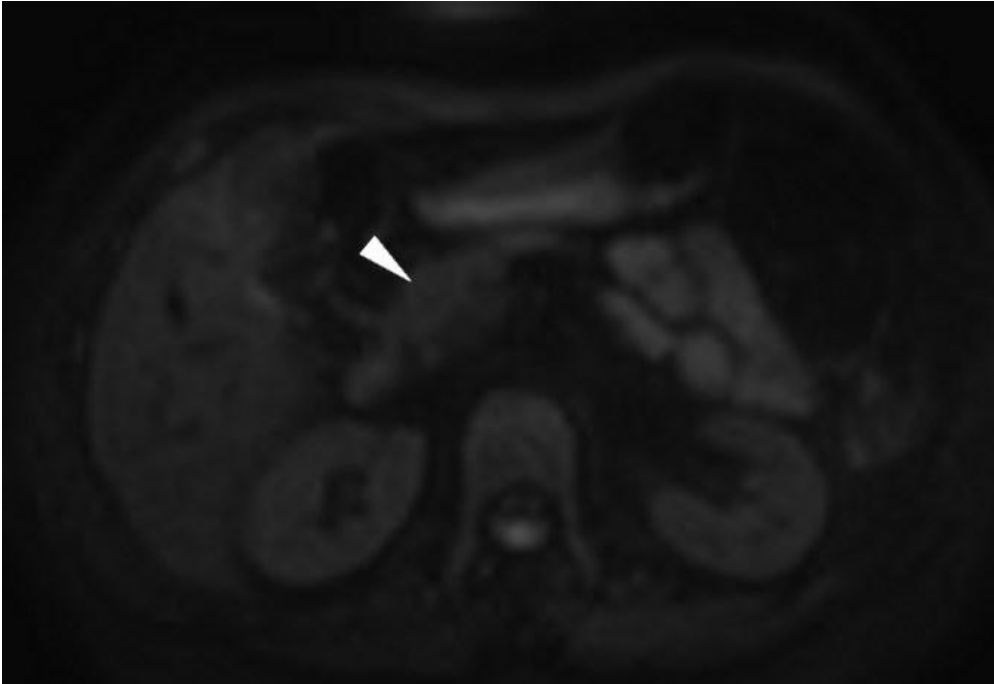
d



Description: Apparent diffusion coefficient (ADC) maps (c,d) showed corresponding strong hypointensity of the pancreas (arrowheads), compared to usual appearance in Figure 6. Measured ADC values ranged between 0.85 and $1.08 \times 10^{-3} \text{ mm}^2/\text{s}$. **Origin:** Tonolini M, Radiology Department, "Luigi Sacco" University Hospital – Milan (Italy)

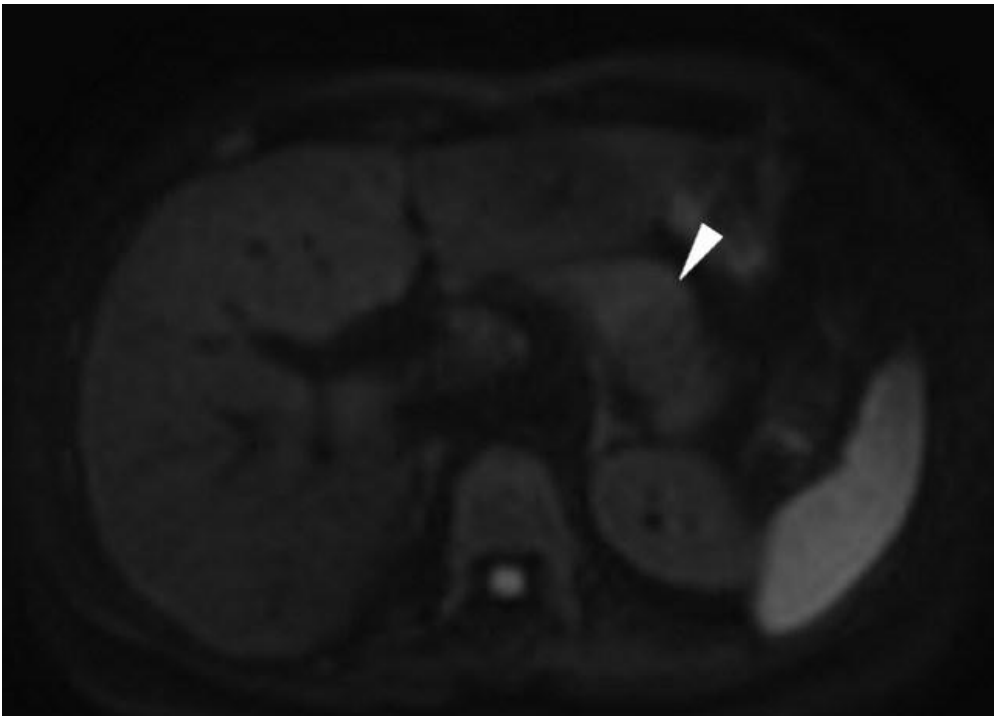
Figure 6

a



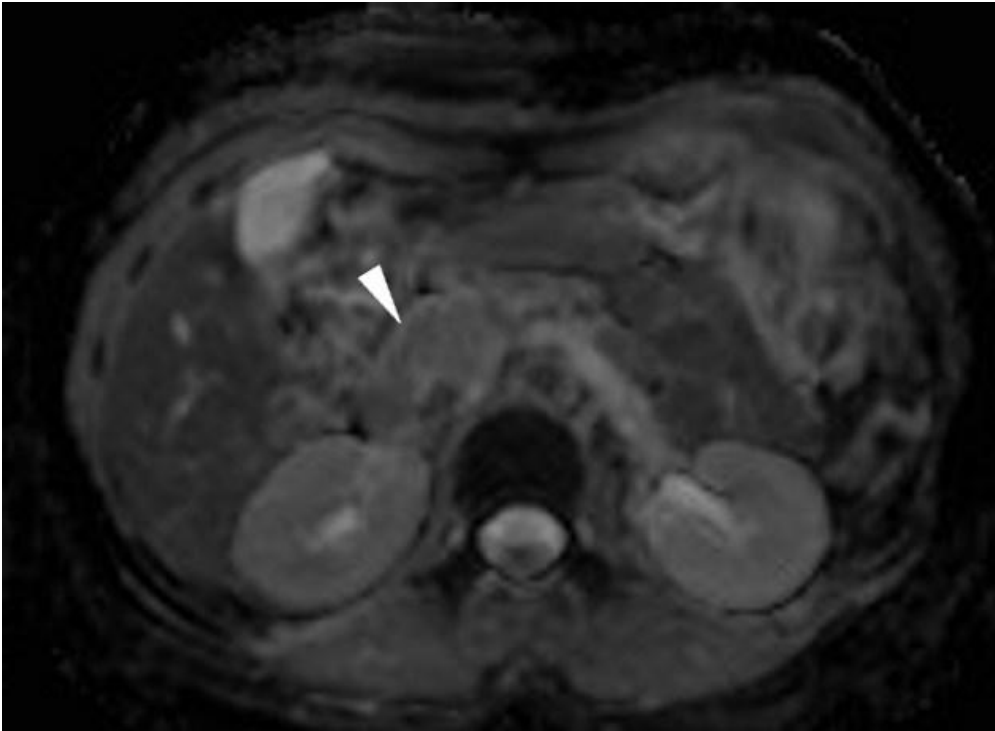
Description: Showed for comparison, diffusion-weighted (b=800) images (a, b) showed normal signal intensity of a healthy pancreatic gland (arrowheads). **Origin:** Tonolini M, Radiology Department, "Luigi Sacco" University Hospital – Milan (Italy)

b



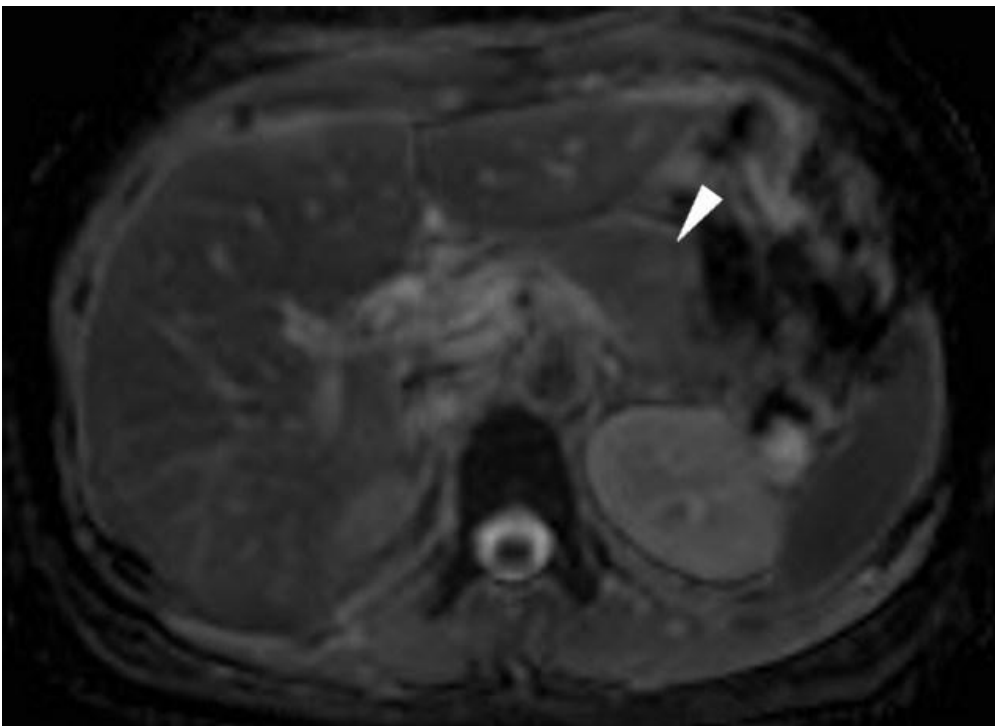
Description: Showed for comparison, diffusion-weighted (b=800) images (a, b) showed normal signal intensity of a healthy pancreatic gland (arrowheads). **Origin:** Tonolini M, Radiology Department, "Luigi Sacco" University Hospital – Milan (Italy)

c



Description: Corresponding apparent diffusion coefficient (ADC) maps (c,d) showed normal intensity of the healthy pancreatic gland (arrowheads), to be compared with Figure 5. **Origin:** Tonolini M, Radiology Department, "Luigi Sacco" University Hospital – Milan (Italy)

d



Description: Corresponding apparent diffusion coefficient (ADC) maps (c,d) showed normal intensity of the healthy pancreatic gland (arrowheads), to be compared with Figure 5. **Origin:** Tonolini M, Radiology Department, "Luigi Sacco" University Hospital – Milan (Italy)