

Multiple amebic hepatic abscesses communicating with the biliary tree

Published on 31.07.2000

DOI: 10.1594/EURORAD/CASE.469

ISSN: 1563-4086

Section: Abdominal imaging

Imaging Technique: Ultrasound

Imaging Technique: CT

Imaging Technique: CT

Imaging Technique: MR

Imaging Technique: MR

Imaging Technique: CT

Case Type: Clinical Cases

Authors: I. Tritou, P. Prassopoulos, A. Voloudaki, E. Ganotakis*, N. Gourtsoyannis

Patient: 14 years, female

Clinical History:

A previously healthy young patient admitted with abdominal pain, high-grade fever, leukocytosis, and diarrhea.

Imaging Findings:

A 14 years old female was admitted to hospital with high-grade fever (up to 39.50 C), diarrhea, malaise, anorexia and abdominal pain for the past two days. Physical examination revealed severe tenderness on palpation in the right upper and lower quadrant. Laboratory tests showed anemia (haemoglobin 9.8 gr/dl), severe leukocytosis (WBC:26700/ μ L), and high alkaline phosphatase (187 U/L) and LDH (160 U/L) levels. The patient underwent abdominal Ultrasonogram (US), Computed Tomography (CT) and Magnetic Resonance Imaging (MRI) that revealed multiple round lesions scattered throughout the hepatic parenchyma. The lesions, measuring 2-16 mm were hypoechoic on US without a clearly discernible wall and a faint posterior acoustic enhancement. The foci appeared hypodense with peripheral ring-like enhancement on post-contrast CT. A slightly hypodense zone of liver parenchyma surrounding the larger of the lesions was observed. Mild thickening of the intestinal wall in the terminal ileum was also shown on CT. On T1-w MR images the lesions were of low signal intensity with indistinct borders demonstrating ring enhancement after intravenous gadolinium administration. The foci were of very high signal intensity on T2-w images and a halo of moderately high signal intensity in the surrounding liver parenchyma attributed to edema was disclosed. MR cholangiography (MRC) images demonstrated the cystic lesions and indicated communication with the biliary tree for the two larger foci. Empirical treatment was administered, but the patient remained febrile three days after the initiation of therapy. A fine needle aspiration biopsy of one peripheral lesion yielded in fluid with bile confirming the MRC images. The diagnosis was based on blood cultures, stool examinations and serological tests, and appropriate pharmaceutical treatment was administered. Improvement in patient's symptoms occurred two days later. US and MR imaging showed reduction in the number and size of the lesions. The patient discharged from hospital 20 days after admission, free of symptoms. US and MR imaging at that time showed obliteration of all hepatic lesions.

Discussion:

Entamoeba histolytica is the responsible protozoan for amebic infection. It is primarily affecting the colon through the contaminated food or water. The microorganism is endemic worldwide (1). Liver abscess is the most common extraintestinal complication of the infection occurring in 3-9% of cases (1). Presenting symptoms include acute pain in the right upper quadrant, high-grade fever and diarrhea. The diagnosis is based on blood cultures, serological tests and stool examination as in our case. However, it is worth noting that serology for amebiasis has a significant false negative rate (1), so repetition of these tests may be necessary when the disease is clinically suspected. During treatment with metronidazole the number and size of the lesions were progressively decreased (2). Amebic abscesses without appropriate treatment may extend to the chest wall, pleura, or adjacent visceral organs. Imaging characteristics were rather typical in our case and have been sporadically described in the literature (1,3). The only unusual finding in our patient was the communication of some of the abscesses with the biliary tree indicated on MR cholangiography and confirmed by CT-guided aspiration biopsy. MRC was performed employing a projectional FSE sequence. A multislice HASTE sequence may be more appropriate to demonstrate communication of the cysts with the biliary tree. Unfortunately, the young patient was not cooperative at the end of the MR study in order to obtain additional MR images with the HASTE technique. ERCP was not performed in our case because there was no clear indication for an invasive diagnostic study. CT-guided fine needle aspiration is required when fever persists despite antibiotic therapy in order to exclude the presence of pyogenic abscesses and usually yields no organisms but only necrotic hepatocytes and white cells (1). The differential diagnosis includes pyogenic abscesses that are usually complication of a pre-existing disease and have not a rapid onset of symptoms (1), fungal abscesses that invariably affect immunocompromised people (1,3), multiple bile duct hamartomas (Von Meyenburg complex) that are small and exhibit no enhancement (4), Caroli's disease (5), and cystic metastases (3). We present US, CT and especially MR imaging findings of amebic hepatic abscesses in an immunocompetent young patient. Of specific interest was the MR cholangiography evidence of abscesses communicating with the biliary tree.

Differential Diagnosis List: Multiple amebic hepatic abscesses communicating with the biliary tree

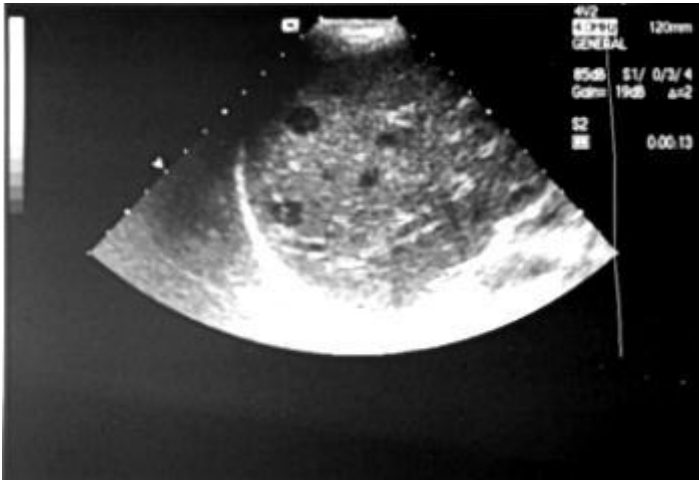
Final Diagnosis: Multiple amebic hepatic abscesses communicating with the biliary tree

References:

- Ralls PW. Focal inflammatory disease of the liver. *Radiol Clin North Am* 1998; 36(2):377-389. (PMID: [9520989](#))
- Hoffner RJ, Kilagbalian T, Esekogwu VI, Henderson SO. Common presentations of amebic liver abscesses. *Ann Emerg Med* 1999; 34(3):351-55. (PMID: [10459092](#))
- Mendez RJ, Schiebler ML, Outwater EK, Kressel HY. Hepatic abscesses: MR Imaging findings. *Radiology* 1994;190:431-436. (PMID: [8284394](#))
- Wohlgemuth WA, Bottger K, Bohndorf K. MRI, CT, US and ERCP in the evaluation of bile duct hamartomas (von Meyenburg complex): a case report. *Eur Radiol* 1998; 8:1623-1626. (PMID: [9866774](#))
- Asselah T, Ernst O, Sergent G, L'hermine C, Paris JC. Caroli's disease: a magnetic cholangiopancreatography diagnosis. *Am J Gastroenterol* 1998; 93(1):109-110. (PMID: [9448187](#))

Figure 1

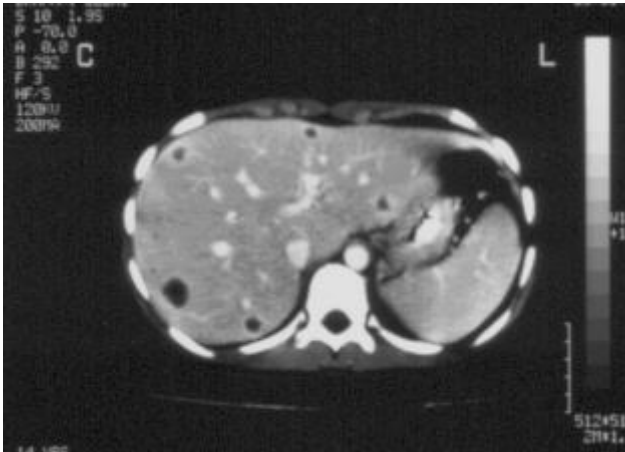
a



Description: Abdominal Ultrasonography (US) shows a few discrete, hypoechoic foci in the right hepatic lobe with the larger lesions exhibiting a faint posterior acoustic enhancement. **Origin:**

Figure 2

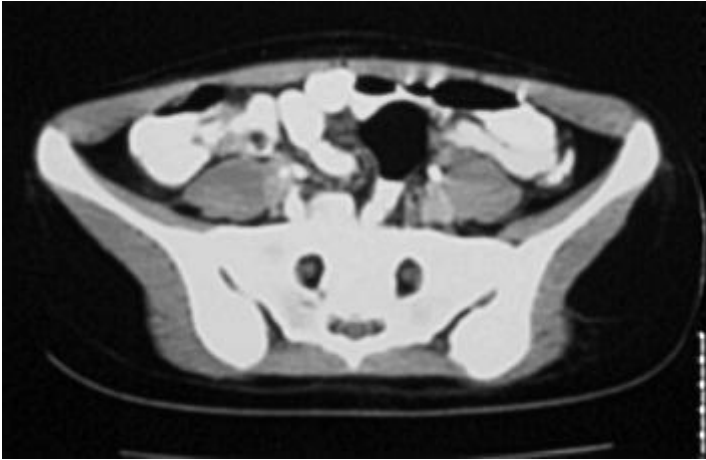
a



Description: Contrast-enhanced abdominal CT section 3 cm above the porta hepatis reveals the presence of multiple rather well circumscribed hypodense cystic-like lesions disseminated in both hepatic lobes, measuring from a few millimeters up to approximately 1,6 cm. The lesions demonstrate peripheral enhancement. **Origin:**

Figure 3

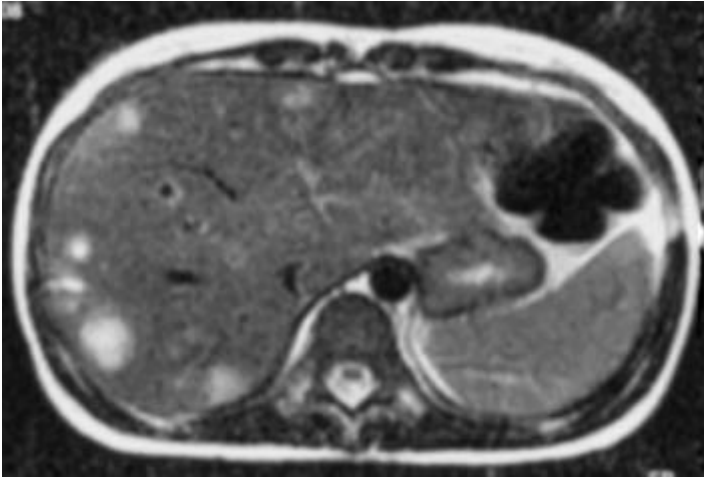
a



Description: CT section at the level of the ileocecal valve. A mild circumferential thickening of the terminal ileum wall is shown. **Origin:**

Figure 4

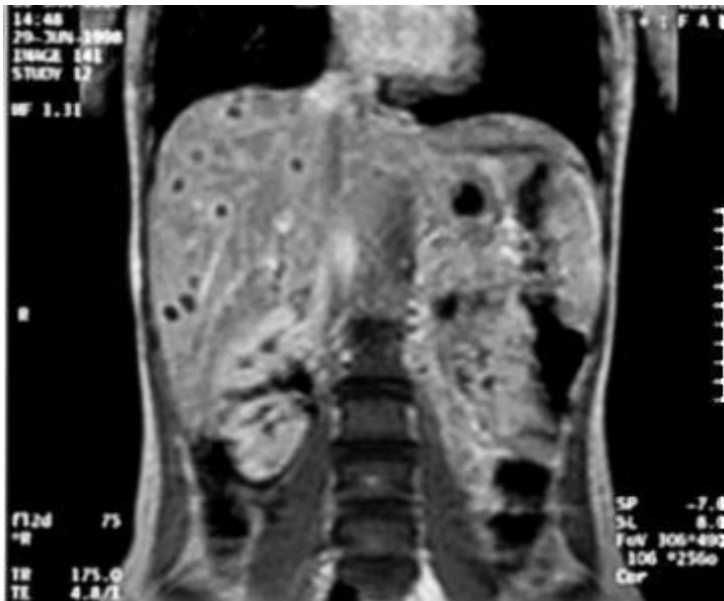
a



Description: Axial T2-weighted image. Presence of multiple foci of high signal intensity, disseminated in both hepatic lobes. Note the presence of a perilesional halo of moderately high signal intensity in the surrounding liver parenchyma, due to edema. **Origin:**

Figure 5

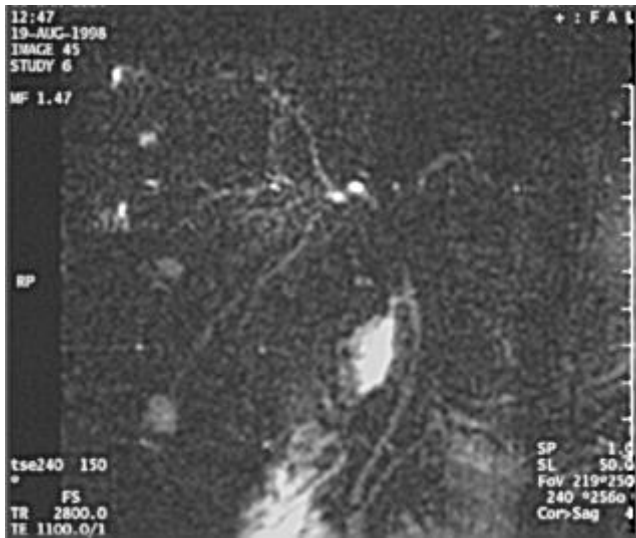a



Description: Coronal T1-weighted image 3 minutes after intravenous contrast medium administration. The multiple rounded lesions demonstrate ring-like enhancement. **Origin:**

Figure 6

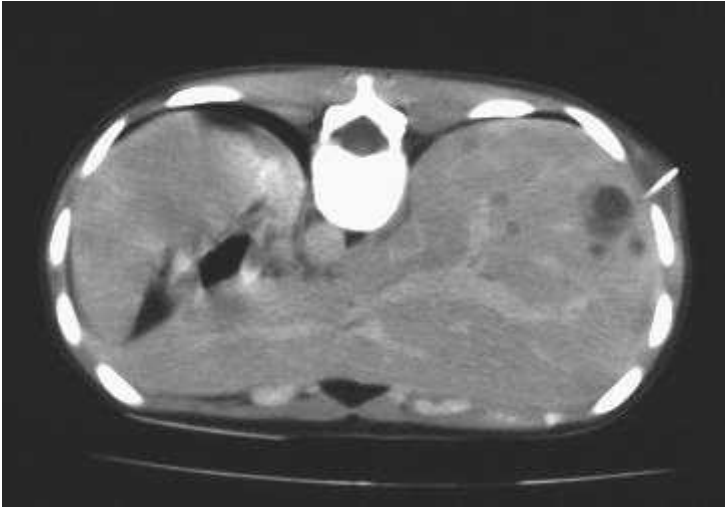a



Description: MR cholangiography shows the cystic lesions and indicates communication with the biliary tree for two of them. **Origin:**

Figure 7

a



Description: CT-guided fine needle aspiration of a peripheral cystic lesion. The fluid was of billous origin and yielded necrotic hepatocytes and white cells but no organisms. **Origin:**