

Extensor digitorum brevis manus:

US and MRI findings

Published on 22.10.2006

DOI: 10.1594/EURORAD/CASE.3328

ISSN: 1563-4086

Section: Musculoskeletal system

Imaging Technique: Ultrasound

Case Type: Clinical Cases

Authors: Reus M, Martınez F, Abellán D, Alonso J, Vázquez V

Patient: 38 years, male

Clinical History:

A 38-year-old man presented with a prominence in the dorsum of the right hand that was more evident during the active extension of the fingers and painful after doing heavy manual work.

Imaging Findings:

A 38-year-old man presented with a pain in the dorsum of the right wrist, which he had developed while practising heavy manual work in the past month. At physical examination, a prominence in the dorsum of the right hand, more exactly in the distal part of the wrist, between the extensor tendons of the index and middle fingers, was detected. The prominence was more evident when the fingers were fully extended. Suspecting a ganglion, a sonography of the dorsum of the right hand and wrist was performed, which evidenced a soft tissue mass with muscle-like echographic texture (Fig. 1) that showed morphological changes during the active extension of the fingers (Fig. 2). MRI demonstrated the presence of an ovoid mass similar to a normal muscle (Figs. 3 and 4) in the dorsum of the hand. According to these findings in sonography and MRI scan, the final diagnosis made was that of a right extensor digitorum brevis manus muscle.

Discussion:

The extensor digitorum brevis manus (EDBM) is a relatively rare supernumerary muscle of the dorsum of the hand. There is a slight predominance of occurrence in males. It is estimated to be two to three of the cases and there are no significant differences of it being bilateral in 54 locations between both hands. It is a single belly muscle originating in the distal epiphysis of the radius, the dorsal radiocarpal ligament, or the wrist-joint capsule. It has an insertion most commonly into the hood of the second extensor, followed by the hood of the third extensor and sometimes the second and third fingers. The tendon of the extensor of the index is absent in the cases in which the EDBM muscle inserts into the second finger. The EDBM was innervated by the posterior interosseous nerve and its blood supply was provided by the posterior interosseous artery. EDBM usually is asymptomatic, although repetitive movements of the wrist and hand may cause pain in the dorsum of the wrist. The pain is likely to be a consequence of muscle hypertrophy and of impingement of the muscle against the extensor retinaculum. In the physical examination, the EDBM may be misdiagnosed as a ganglion or soft-tissue tumors. A characteristic finding of the EDBM is that the prominence in the dorsum of the hand increases in size with the active extension of the fingers. Sonography reveals the presence of a soft-tissue mass with muscle-like echo texture, which suffers morphological changes during the active extension of the fingers. MRI scans are helpful in distinguishing, in a non-invasive way, EDBM from tumors, thereby avoiding surgery. The treatment depends on the severity of the symptoms. When the symptoms are severe, conservative treatment with anti-inflammatory drugs and immobilization may be unsuccessful. Although division of the retinaculum may provide symptomatic relief, the excision of the muscle is usually

recommended. However, resection of EDBM should be avoided in those cases in which it compensates for the absence of the extensor indicis proprius.

Differential Diagnosis List: Accessory extensor digitorum brevis manus muscle.

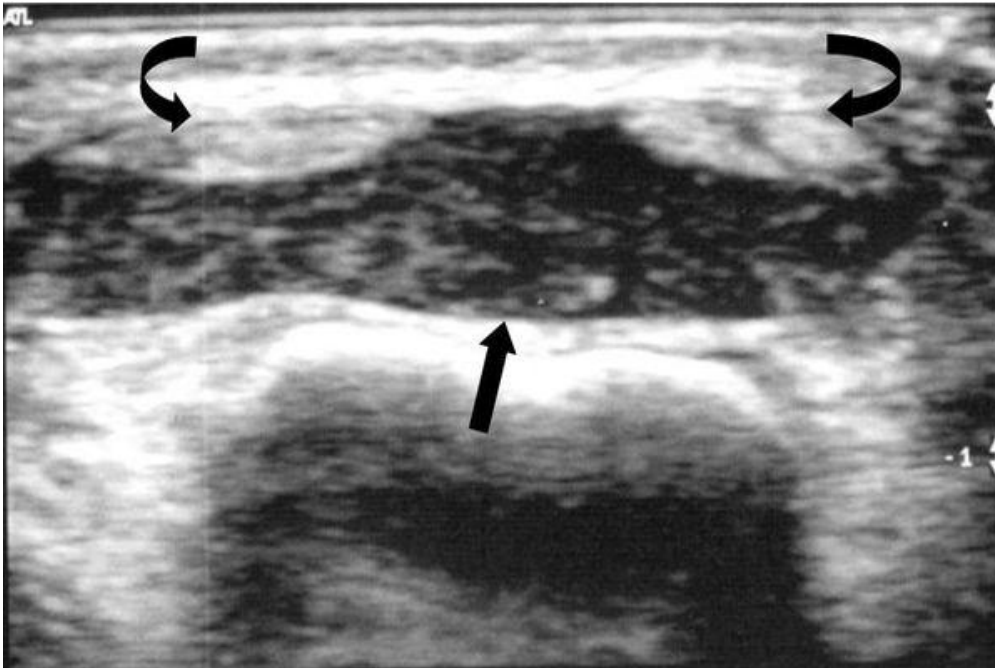
Final Diagnosis: Accessory extensor digitorum brevis manus muscle.

References:

- Ouellette H, Thomas BJ, Torriani M. Using dynamic sonography to diagnose extensor digitorum brevis manus. *AJR Am J Roentgenol*. 2003 Nov;181(5):1224-6. (PMID: [14573408](#))
- Nakano M, Watanabe Y, Masutani M. A case of extensor digitorum brevis manus. *Dermatol Online J*. 2003 Dec;9(5):21. (PMID: [14996394](#))
- Rodriguez-Niedenfuhr M, Vazquez T, Golano P, Parkin I, Sanudo JR. Extensor digitorum brevis manus: anatomical, radiological and clinical relevance. A review. *Clin Anat*. 2002 Jun;15(4):286-92. (PMID: [12112357](#))
- Dossing KV. Clinical importance of the extensor digitorum brevis manus muscle. Case report. *Scand J Plast Reconstr Surg Hand Surg*. 1994 Mar;28(1):77-8. (PMID: [8029658](#))
- Fakih RR, Thomas R, Mansour A. The extensor digitorum brevis manus. A case report. *Bull Hosp Jt Dis*. 1997;56(2):115-6. (PMID: [9220106](#))

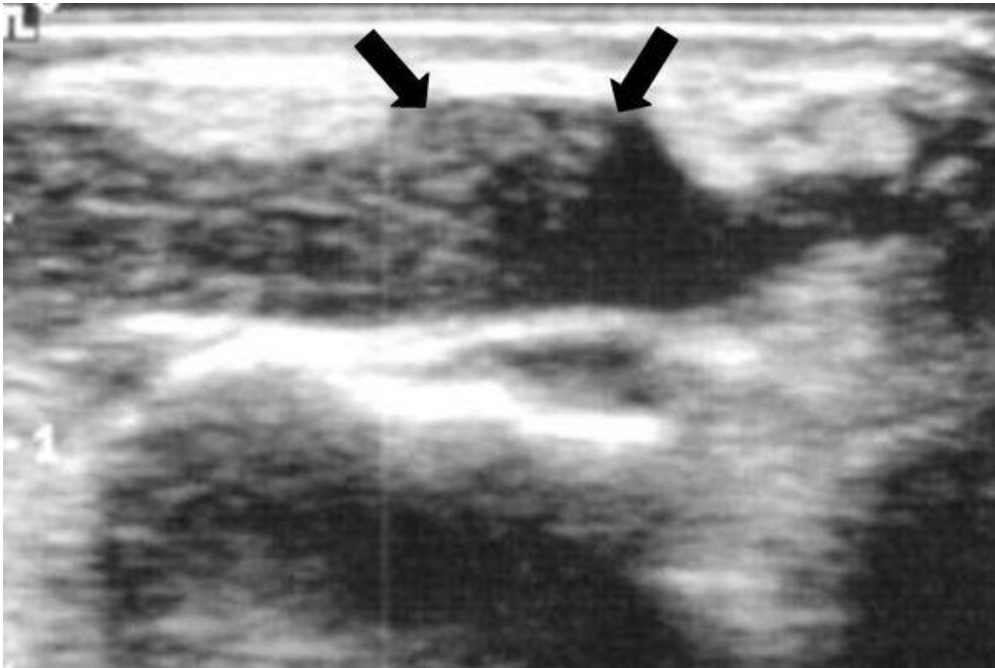
Figure 1

a



Description: A transverse gray-scale sonograph of the dorsum of the hand showing anomalous muscle with a typical echo texture (straight arrow), located between the extensor tendons of the third and fourth digits (curved arrows). **Origin:**

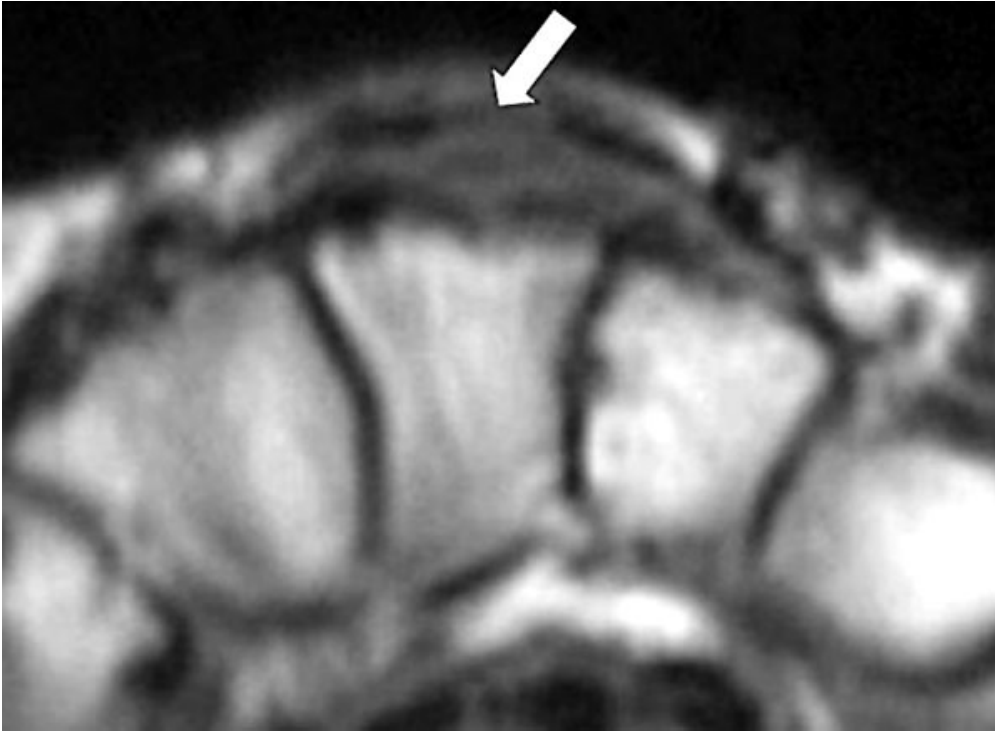
b



Description: A transverse gray-scale sonograph of the dorsum of the hand obtained during active finger extension, showing a muscle protruding dorsally between the third and fourth digits. **Origin:**

Figure 2

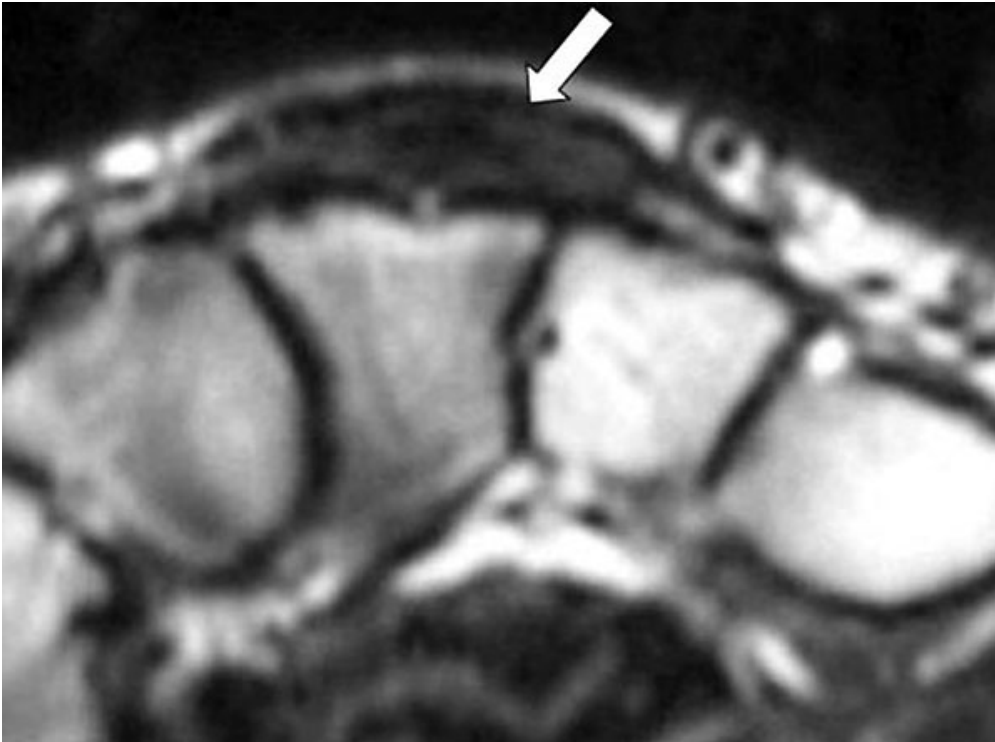
a



Description: A T1-weighted axial MRI of the hand showing an ovoid mass of an intermediate signal intensity, similar to normal muscle, surrounding the extensor digitorum communis tendons (arrow).

Origin:

b



Description: A T2-weighted axial MRI of the hand showing, just as in T1, an ovoid mass of an intermediate signal intensity (arrow). **Origin:**