

Acute ?nterstitial Pneumonia Associated with Spontaneous Pneumothorax

Published on 26.02.2008

DOI: 10.1594/EURORAD/CASE.5288

ISSN: 1563-4086

Section: Chest imaging

Case Type: Clinical Cases

Authors: Elmalı M¹;, Gokce E¹;, Ceyhan
M¹;, Doughanji R¹;, Celenk C¹;

¹;Ondokuz Mayıs University, Department of
Radiology, Samsun, Turkey e-mail:

muzafel@yahoo.com.tr

Patient: 22 years, female

Clinical History:

A 22 year old female patient presented to the emergency unit with a sudden onset of cough and dyspnea.

Imaging Findings:

There was no history of exposure to toxic agents; nor had the patient taken any drugs. The patient was reportedly non-smoker and there was no recent history of contact with house hold pets (cats, dogs or birds). Initial chest x-ray radiograph displayed diffuse patchy alveolar densities. CT scan showed bilateral diffuse septal interstitial thickening, ground glass appearance and areas of irregular patchy consolidation (fig.1). In addition bronchovascular structures were distorted and traction bronchiectasis and right sided pneumothorax was evident (fig.2). The patient did not respond to 10 days of antibiotic and supportive treatment. After bronchoscopic biopsy and bronchioalveolar lavage yielded nonspecific results open lung biopsy was performed reporting non specific interstitial pneumonia. Follow – up HRCT performed after 2 weeks displayed decreased alveolar infiltration and predominance of interstitial findings. Moreover, bilateral cystic lesions had developed along with a bullous lesion within the right upper lobe (fig.3).

Discussion:

Acute interstitial pneumonia (AIP) is an idiopathic lung disease characterised by rapidly progressive dyspnea developing over days to weeks. AIP is synonymous with Hamman Rich syndrome. It is defined as rapidly progressive respiratory failure occurring in patients without pre-existing lung disease or extrathoracic disorders known to be associated with lung involvement. Patients with AIP have a poor prognosis, with reported mortality rates of 60-100%. The pathologic hallmark of AIP is diffuse alveolar damage. Histopathological investigation is always necessary for a definitive diagnosis of AIP. The chest radiographic and high-resolution CT scan manifestations of AIP are bilateral and sometimes patchy, and there are alveolar densities associated to areas of ground glass attenuation. But these findings are nonspecific. Acute onset is a very important clue in the diagnosis of AIP. Traction bronchiectasis, bronchiolitis, fibrosis and cysts (honey combing) develop with time. AIP is considered among idiopathic interstitial pneumonias. This kind of diseases are reported to occasionally develop acute complications such as pneumothorax and pneumomediastinum. If CT displays paranchymal and interstitial findings coupled with pneumothorax the initial differential diagnosis should include bronchiolitis obliterans, AIP, idiopathic pulmonary fibrosis group disease, cystic fibrosis, langerhans cell histiocytosis, lymphangiomyomatosis, hypersensitivity pneumonia and

pneumocysts jirovecii pneumonia.

Differential Diagnosis List: Acute interstitial pneumonia

Final Diagnosis: Acute interstitial pneumonia

References:

Olson J, Colby TV, Eliot CG. Hamman-Rich syndrome revisited. Mayo Clin Proc.1990; 65:1538-1548. (PMID: [2255216](#))

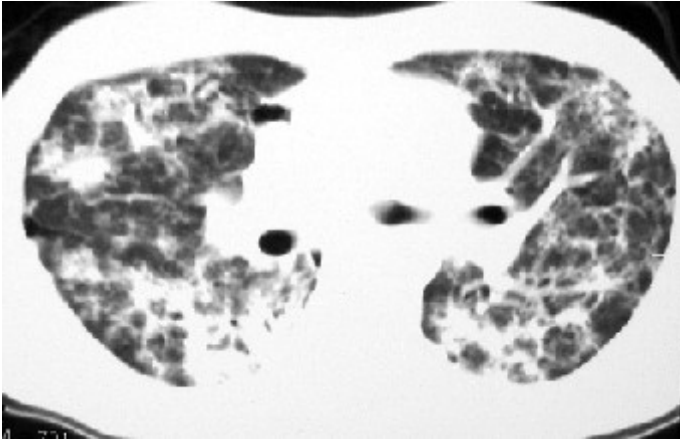
Primack SL, Hartman TE, Ikezoe J, et al. Acute interstitial pneumonia: radiographic and CT findings in nine patients. Radiology1993;188: 817-820. (PMID: [8351354](#))

Müller NL, Colby TV. Idiopathic interstitial pneumonias: high resolution CT and histologic findings. Radiographics 1997;17: 1016-1022. (PMID: [9225401](#))

Bouros D, Nicholson AC, Polychronopoulos V, Bois RM. Acute interstitial pneumonia. Eur Respir J 2000;15:412-418. (PMID: [10706513](#))

Figure 1

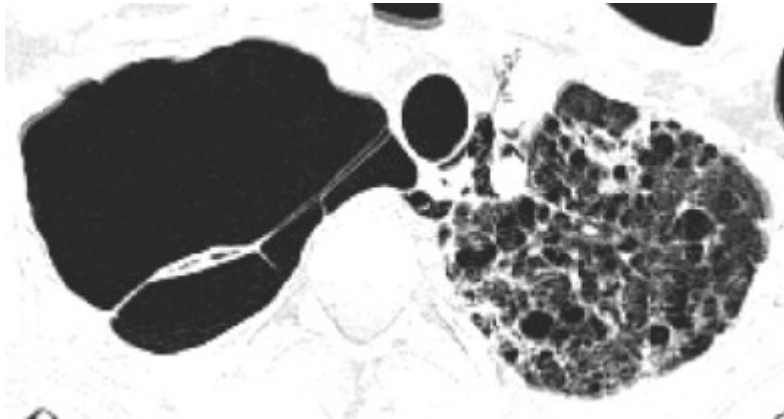
a



Description: Axial CT showing bilateral diffuse ground glass and patchy consolidation **Origin:**

Figure 2

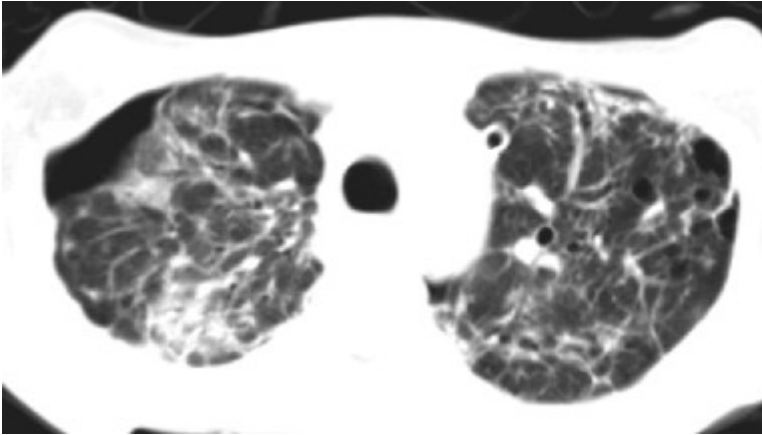
a



Description: HRCT scan showing interstitial thickening and cystic lesions on the left upper lobe and a bullous lesion on the right upper lobe **Origin:**

Figure 3

a



Description: Axial CT showing right sided pneumothorax and bronchovascular distortion **Origin:**